

Surgical treatment for urethral and vesical sling extrusion: case series

Tratamento cirúrgico para extrusão uretral e vesical de sling: série de casos

Raphael de Jesus Moreira¹, Luis Gustavo Toledo², Victor Espinheira Santos³, Marjo Denison Cadernuto Perez⁴, Moacyr Fucs⁵

Abstract

Urinary incontinence is a common problem in the female population affecting physical, emotional, psychological, social and sexual well-being that has a major impact on women's quality of life. Despite numerous studies showing high rates of cure, post-surgical complications are often reported, including urethral and vesical sling extrusion. The aim of this study is to report a series of cases of extrusion and its various particularities, emphasizing the different treatment options, given that the same is not a routine complication.

Keywords: Suburethral slings, Urinary incontinence, Urologic surgical procedures/methods

Resumo

A incontinência urinária é problema comum na população feminina, comprometendo o bem-estar físico, emocional, psicológico, social e sexual, com forte impacto à qualidade de vida da mulher. Apesar de vários estudos mostrarem

altas taxas de cura, complicações operatórias são relatadas, incluindo a extrusão vesical e uretral de sling. O objetivo do presente trabalho é relatar uma série de casos de extrusão e suas diversas particularidades, dando ênfase aos diferentes opções de tratamento, tendo em vista que a mesma, não é uma complicação rotineira.

Descritores: Slings suburetrais, Incontinência urinária, Procedimentos cirúrgicos urológicos/métodos

Introduction

Urinary incontinence is a common problem in the female population affecting physical, emotional, psychological, social and sexual well-being and has a major impact on the women's quality of life⁽¹⁾.

To date, over 100 different surgical techniques have been described. Improved understanding of the physiopathology of stress urinary incontinence (SUI) has led to the development of novel techniques, such as minimally invasive surgery involving tension-free slings. Cure rates are typically around 85% in follow-ups of over five-years, and advantages of the procedure include fewer incisions, less local anesthetic, shorter hospital stay and swifter resumption of daily living activities of patients⁽²⁾.

Despite numerous studies showing high rates of cure, post-surgical complication are often reported, including urethral and vesical sling extrusion⁽⁴⁻⁵⁾. Therefore, the aim of this study is to report a series of cases of extrusion and its various particularities, emphasizing the different treatment options, given that the same is not a routine complication.

Case 1

LRT, a 60-year-old, São Paulo-born, married woman was referred to the urology service of Santa Casa hospital with an 11-month history of recurrent urinary infection. The patient reported sporadic urinary loss under straining. Patient history: two vaginal deliveries; transobturator sling in April 2010. No diabetes or arterial hypertension was reported. Exam findings:

1. Medical Resident of the Urology Department of Irmandade da Santa Casa de Misericórdia de São Paulo

2. Professor of Santa Casa Medical School of São Paulo. Department of Surgery

3. Urology Resident of the Surgery Department of Irmandade da Santa Casa de Misericórdia de São Paulo

4. Associate professor of Santa Casa Medical School of São Paulo. Department of Surgery

5. Assistant professor of Santa Casa Medical School of São Paulo. Department of Surgery

Work was developed: Urology Department of Irmandade da Santa Casa de Misericórdia de São Paulo

Address for correspondence: Raphael de Jesus Moreira. Rua: Jaguaribe, 252 apt 407 - Vila Buarque - 02524 050 - São Paulo - SP - Brasil. Phone: (55+11) 78761097. E-mail: raphaeljm@hotmail.com

Disclosure: none of the authors has any conflicts of interest with the content of this article.

Contribution to the Manuscript: All of the authors participated in the conception of this study, in the analysis and interpretation of the results and in the elaboration and critical review of the final manuscript.

hypotrophic vagina, with no cystocele or rectocele, and no loss of urine during straining maneuver. Cystoscopy disclosed evidence of mesh transfixation to the urethra and left lateral wall of the bladder (Fig.1). The patient was submitted to mesh removal in April 2011 (Fig.2). The incision was made to the anterior wall of the vagina. Urethra and bladder was sutured using PDS 4.0 cord followed by a Martius flap repair. The woman was discharged on the first post-operative day with a urinary catheter for 10 days. Thirty days after surgery, the patient presented with strain urinary incontinence but no urinary fistula and is awaiting surgery for a new sling.

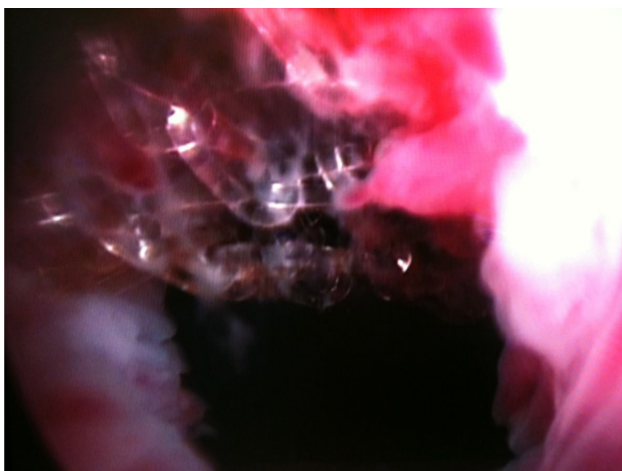


Figure 1 - Sling transfixing urethra and bladder

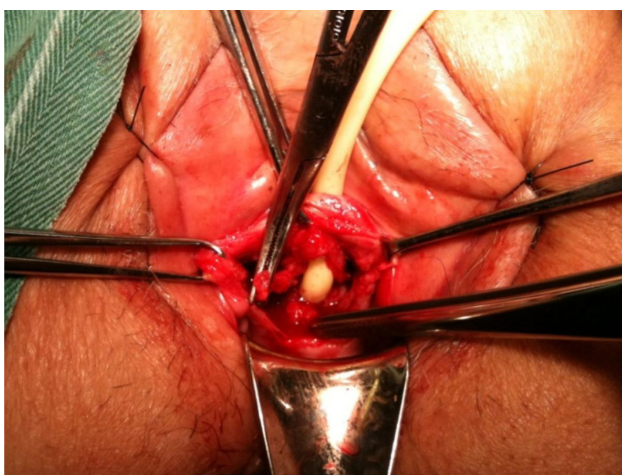


Figure 2 - Opening of urethra with detachment of mesh

Case 2

RWM, a 57-year-old married woman, was submitted to rectopubic sling in September 2009. The patient reported onset of recurrent urinary infection and vaginal discharge of purulent secretion two months after surgery. Patient history: diabetes mellitus (G2P2NA0).

Urethrocystoscopy revealed evidence of sling mesh erosion in the urethra. In December 2010, the patient was referred to Santa Casa de São Paulo hospital and underwent a procedure for mesh removal via the vaginal route. The urethra was opened and vesical trigone exposed with careful identification of the urethral meatus. Urethra and bladder were sutured using PDS 4.0 cord. Patient was discharged on the 1st PO day. The urinary catheter was withdrawn after 15 days and the patient evolved with moderate incontinence.

Case 3

RM, a 54-year-old married women (G4P3nA1) was submitted to transobturator sling in 2009 in the state of Bahia. The patient evolved with recurrent urinary infection and symptoms of irritation. Cystoscopy revealed patent ureter and sling mesh in the vesical trigone and left lateral wall, besides adherent vesical calculus. The patient was admitted to Santa Casa Hospital on 20th June 2011 for removal of the foreign body. Given bladder compromise only, a retropubic approach was used which involved opening of the bladder and removal of the mesh. The patient was discharged on the 2nd post-operative day. The bladder catheter was withdrawn after 10 days and patient evolved with continence and no signs of urinary fistula.

Discussion

Tension-free suburethral slings have become a first line approach for the management of stress urinary incontinence⁽²⁾.

Various synthetic materials have been developed and a substantial reduction in surgical morbidity attained. The use of synthetic mesh reduces surgery time and precludes potential morbidity at the harvest site of the autologous graft. Meshes differ in terms of their constituent components and fiber, weave, porosity and flexibility properties. These properties affect tissue response and the capacity for incorporation into host tissue or for fighting infection⁽³⁾.

Despite numerous studies showing high rates of cure using the retropubic approach, peri-operative complications are often reported, including intestinal, vascular and bladder injuries. In a bid to minimize these complications, a procedure by which the sling is introduced via the obturator foramen, thereby avoiding the tunnel through the retropubic space. Transmuscular insertion via the obturator muscles through a subcutaneous tunnel confers anchorage and anatomic reinforcement to the ureteropelvic ligament^(4,5).

In the transobturator technique, the retropubic space is not invaded, reducing the risk of bladder, vascular or intestinal injury and dispensing with the

need for perioperative cystoscopy.

Palma et al⁽⁶⁾, reported shorter surgery time using the transobturator technique than the retropubic approach, as well as a lower rate of complications such as bladder perforation (2.3% and 0%, respectively) and post-operative urgency (20.6% and 10%, respectively). Perforation in the vaginal fornix area occurs when the dissection of the vaginal wall is not sufficiently deep. It is important to verify, upon passing the needle through the obturator orifices, that the integrity of the vaginal cavity is conserved, since inadvertent exposure of the mesh can lead to subsequent sequelae.

Infectious complications including inguinal and obturator abscesses as well as perineal cellulite have been reported, while rarer complications such as infected hematoma and necrotizing fasciitis have also been observed^(4,5).

Bladder voiding problems are generally transient and the result of excessive tension in the sling, location proximal to the vesical neck or due to placement of the mesh in patients with hypocontractile bladder, resolving normally with intermittent catheterization for a few days. In the event of complete obstruction urethrolisis may be necessary⁽⁵⁾.

Conclusion

Although a rare event, surgeons should remain alert to the risk of bladder and urethra perforation

by the transobturator and retropubic sling, so as to ensure early diagnosis and reduced patient morbidity.

The approach for this patient group is preferably via the vaginal route for cases with urethra compromise, and via the retropubic route with vesical opening in the case of transfixated bladder meshes only.

References

1. Samuelsson E, Victor A, Svardsudd K. Determinants of urinary incontinence in a population of young and middle-aged women. *Acta Obstet Gynecol Scand*. 2000;79:208-15.
2. Novara G, Ficarra V, Boscolo-Berto R, Secco S, Cavalleri S, Artibani W. Tension-free midurethral slings in the treatment of female stress urinary incontinence: a systematic review and meta-analysis of randomized controlled trials of effectiveness. *Eur Urol*. 2007;52:663-78.
3. Clark AL, Gregory T, Smith VJ, Edwards R. Epidemiologic evaluation of reoperation for surgically treated pelvic organ prolapse and urinary incontinence. *Am J Obstet Gynecol*. 2003;189:1261-7.
4. Meschia M, Pifarotti P, Bernasconi F, Guercio E, Maffioli M, Magatti F, et al. Tension-Free vaginal tape: analysis of outcomes and complications in 404 stress incontinent women. *Int Urogynecol J Pelvic Floor Dysfunct*. 2001;12(Suppl 2):S24-S7.
5. Palma P, Riccetto C, Herrmann V, Dambros M, Thiel M, Bandiera S, et al. Transobturator SAFYRE sling is as effective as the transvaginal procedure. *Int Urogynecol J Pelvic Floor Dysfunct*. 2005;16:487-91.

Trabalho recebido: 13/08/2012

Trabalho aprovado: 21/02/2013