

Blister like aneurysm: a review about its endovascular management

Aneurismas *Blister-Like*: uma revisão sobre seu tratamento endovascular

Guilherme Brasileiro de Aguiar¹, Rafael Gomes dos Santos², Vinícius Ricieri Ferraz²,
André Freitas Nunes², Rodrigo Salmeron de Toledo Aguiar², Maurício Jory³, Mario Luiz Marques Conti⁴,
José Carlos Esteves Veiga⁵

Abstract

Introduction: Blood blister-like (BBAs) aneurysms are rare cerebrovascular lesions for which the endovascular treatment methods are reviewed here. The reported pathogenesis varies, and hemodynamic stress, arterial dissection, and arteriosclerotic ulceration have all been described. The excessive fragility of BBAs and their parent vessels, can make microsurgical clipping technically difficult. Surgical treatment is associated with high rates of complications, morbidity, and mortality. The approach to the treatment of BBAs in recent times has shifted from microsurgical treatment to endovascular treatment, thanks to ongoing innovations in regard to endovascular techniques and devices. **Method:** The authors performed a review of available endovascular techniques used for blood blister-like aneurysms treatment. The Pubmed database was used as source search introducing “blood blister-like aneurysm” and “blister aneurysms” as keywords. The most relevant articles and those that focused on endovascular treatment techniques were selected. **Discussion:** Endovascular interventional techniques have evolved as an effective treatment for intracranial aneurysms. Considerable interest has emerged regarding the use of endovascular approaches to

treat BBAs. In some studies, endovascular treatment of BBAs was associated with high rates of complete occlusion and good mid- to long-term neurological outcomes. Various endovascular techniques have been applied to treat BBAs, such as coil embolization, stenting, stent-assisted coiling and flow-diverting stents. **Conclusion:** From the available endovascular techniques, flow-diverting stents appears to be the safest and most effective treatment modality, with a higher rate of complete occlusion of an aneurysm and a lower rate of retreatment. The development of novel flow-diverting stents with decreased thrombogenic properties, may represents a key step forward and increases the potential for flow diversion becoming the gold standard for endovascular treatment of BBAs.

Keywords: Intracranial aneurysm; Aneurysm, ruptured; Carotid artery disease; Subarachnoid hemorrhage; Endovascular procedures

Resumo

Introdução: Aneurismas do tipo blood blister-like (BBAs) são lesões cerebrovasculares raras para as quais os métodos de tratamento com opções endovasculares são revisados aqui. A patogênese relatada varia, e estresse hemodinâmico, dissecação arterial e ulceração arteriosclerótica foram todos descritos. A excessiva fragilidade dos BBAs e de seus vasos portadores podem tornar a clipagem cirúrgica tecnicamente difícil. O tratamento microcirúrgico está associado a altos índices de complicações, morbidade e mortalidade. A abordagem para o tratamento de BBAs nos últimos anos passou a ser preferencialmente por via endovascular, especialmente devido às inovações em curso no que diz respeito às técnicas e dispositivos endovasculares. **Métodos:** Os autores realizaram uma revisão das técnicas endovasculares utilizadas para tratamento de aneurismas blister-like. A plataforma Pubmed foi utilizada para a pesquisa das palavras chaves “blood blister-like aneurysm” e “blister aneurysm”. Os artigos de maior relevância e aqueles que enfatizam as técnicas endovasculares foram selecionados. **Discussão:** As técnicas intervencionistas

1. Instructor Professor at Santa Casa de Sao Paulo School of Medical Sciences. Department of Surgery

2. Neurosurgery Resident at Santa Casa de Sao Paulo - Department of Surgery

3. Attending Neurosurgeon at Santa Casa de Sao Paulo - Department of Surgery

4. Assistant Professor at Santa Casa de Sao Paulo School of Medical Sciences - Department of Surgery

5. Full Professor at Santa Casa de Sao Paulo School of Medical Sciences - Department of Surgery

Institution: Santa Casa de Sao Paulo - Department of Surgery - Discipline of Neurosurgery

Correspondence address: Guilherme Brasileiro de Aguiar. Santa Casa de Sao Paulo School of Medical Sciences - Department of Surgery. Discipline of Neurosurgery. Street: Dr. Cesário Motta Júnior, 61 - Vila Buarque - 01221-020 - São Paulo - SP - Brasil. Telephone: (11) 3367-7700

endovasculares evoluíram como tratamento eficaz para aneurismas intracranianos. Considerável interesse surgiu em relação ao uso de abordagens endovasculares para tratar BBAs. Em alguns estudos, o tratamento endovascular de BBAs foi associado a elevadas taxas de oclusão completa e bons resultados neurológicos a médio e longo prazo. Várias técnicas têm sido aplicadas para o tratamento de BBAs, como embolização endossacular e utilização de stents. Conclusão: Atualmente, a utilização de stents de diversores de fluxo parece ser a modalidade de tratamento mais segura e eficaz, com maior taxa de oclusão completa do aneurisma e menor taxa de necessidade de retratamento. O desenvolvimento de novos stents diversores de fluxo com propriedades trombogênicas reduzidas, aumenta o potencial de tornarem-se o padrão ouro para o tratamento endovascular de BBAs.

Descritores: Aneurisma intracraniano, Aneurisma roto, Hemorragia subaracnóidea, Procedimentos endovasculares

Introduction

Blood blister-like aneurysms (BBAs) are small lesions, sometimes appearing as just a protrusion of the vessel wall and are usually associated with diffuse subarachnoid hemorrhage (SAH) (FIGURE 1) and a severe clinical condition⁽¹⁻²⁾. There is a higher incidence in younger patients with SAH, are

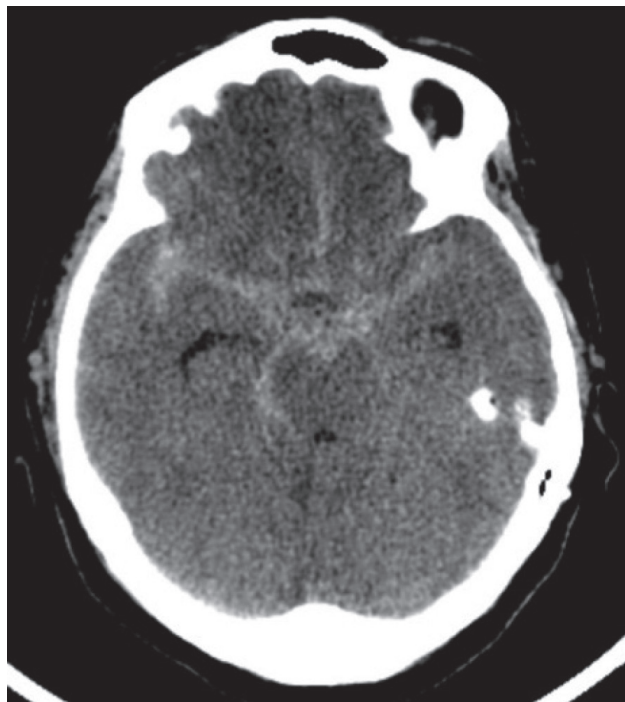


Figure 1. Cranial Computed tomography (axial) demonstrating diffuse subarachnoid hemorrhage, involving basal cisterns and Sylvian fissures. Source: main author's personal archive

associated with hypertension, arteriosclerosis and dissection of the internal carotid artery (ICA), with a right-side and female dominance. They are rapid growth lesions with extremely variable evolution, with a higher tendency to bleed during the intra and post-operative time⁽²⁻⁶⁾.

The diagnosis is, sometimes, a clinical challenge. They are not easily detected at the first angiography due to their small dimensions and unusual site, but because of their rapid growth they appear more evident a few days later and tend to re-rupture^(1,3,7-8). Morphologically they appear as wide-necked shallow outpouchings of non-branching sites commonly of the supraclinoid ICA⁽⁸⁾ (FIGURE 2). Usually, it is necessary intraoperative observation for the final diagnosis, because the angiographic evidence of a saccular shape did not always correlate with the nature of the aneurysm wall^(3,9). They often contain a fragile thin wall and a broad communication with the parent vessel, without an identifiable neck⁽⁸⁾. The evolution of the BBAs into a saccular-like aneurysm in subsequent angiogram is just an illusion, because this new aneurysm does not have the thick wall of a true berry aneurysm^(1,10). Any patient with SAH in an aneurysmal pattern and no detectable berry aneurysm should be carefully scrutinized for a blister aneurysm^(8,11). The CT Angiography diagnosed four of six patients prospectively and five of six retrospectively, therefore a normal Angio-CT does not exclude a BBAs aneurysm.

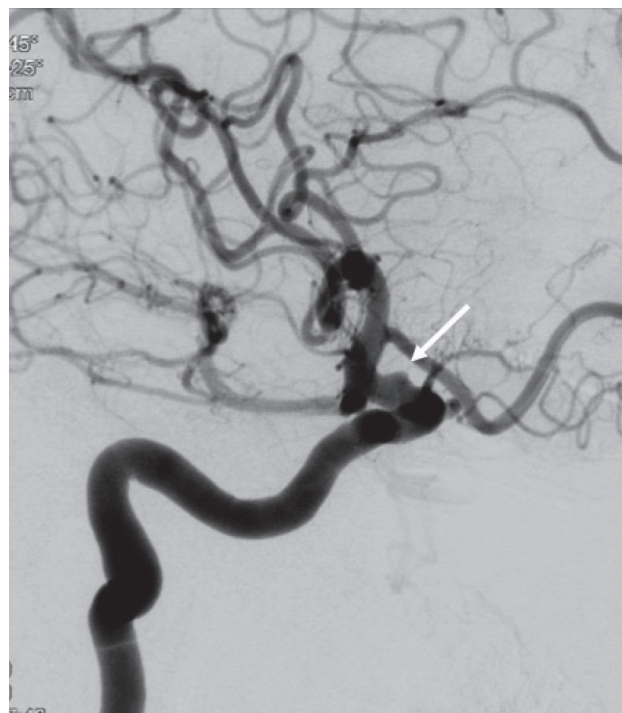

Figure 2. Digital subtraction angiography of the right carotid artery (oblique incidence) demonstrating a blood blister-like aneurysm (arrow). Source: main author's personal archive.

The treatment of BBAs is challenging and includes surgical and endovascular therapeutic methods, often been reported with mixed results. In this review, we focus on the endovascular options.

Method

The authors perform a review of available endovascular techniques used for blood blister-like aneurysms treatment, the Pubmed database was used as source search introducing “blood blister-like aneurysm” and “blister aneurysms” as keywords. The most relevant articles and those that focused on endovascular treatment techniques were selected.

Discussion

Blister aneurysms were first described by Sundt and Murphey in 1969⁽¹²⁾. Also known as blister-type or dorsal wall aneurysm, or ICA anterior wall aneurysm, they arise from non-branching sites of the wall of the supraclinoid internal carotid artery, but have been reported on essentially every cerebral artery^(4,6,8-9). Of all intracranial aneurysms 0,3 -1% are BBAs, and are responsible for 0.9-6.6% of all ICA aneurysms^(3,7,10).

The histological characteristics of blood blister-like aneurysms include focal wall defects covered with clot and fibrous tissue. The focal wall defects may be the result of laceration of the ICA wall caused by ulceration and penetration into the internal elastic lamina, resulting from arteriosclerosis^(1,3). The walls of blood blister-like aneurysms are composed of only normal adventitia, in an abrupt transformation from the sclerotic ICA wall⁽⁷⁾. Dissection of the ICA was observed in some studies in patients with BBAs, suggesting specific pathological features in blister-type aneurysms^(3,13-15). Hemodynamic stress may also influence the occurrence of BBAs.

It is a small hemispherical from the arterial wall^(2,16) most commonly located on the anteromedial wall of the internal carotid artery (FIGURE 3) and are characterized by small size, a fragile wall and a poorly defined broad-based neck^(3,4,9,17) because these particular BBAs are difficult to manage both endovascular techniques as surgically. The incidence of intra and postoperative bleeding is higher than in saccular aneurysms^(2,3). Microsurgical techniques include direct clipping, arterial wrapping and bypass surgery. The endovascular treatment includes coils embolization, balloon-assisted coil embolization, stent-assisted coil embolization, monostenting with open-cell stents placement, stent-in-stent placement and more recently the use of flow-diverting stents.

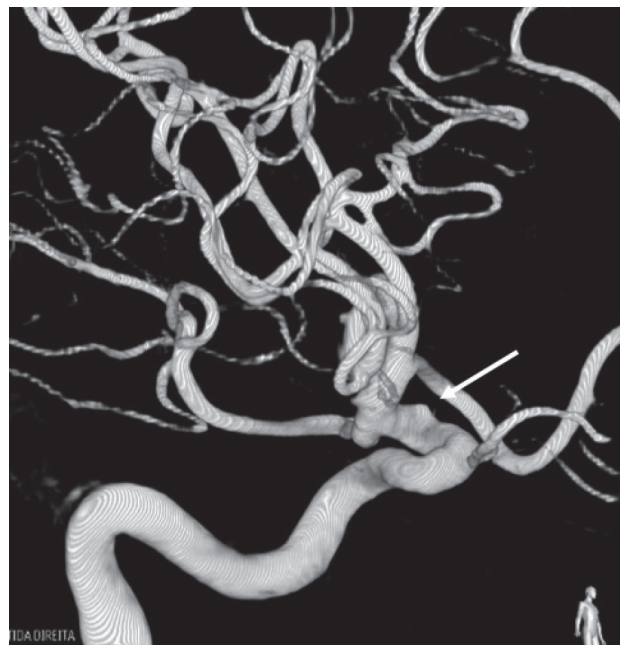


Figure 3. A 3D reconstruction of a digital subtraction angiography of the right carotid artery demonstrating a blood blister-like aneurysm (arrow) on the anteromedial wall of the supraclinoid ICA. Source: main author's personal archive.

Endovascular treatment

Treating the BBAs via endovascular means several techniques have been described including unassisted and stent-supported coil embolization, with varying degrees of success.

In a retrospective study by Matsubara et al, 2011⁽¹⁸⁾ present nine patients that were diagnosed with saccular-shaped BBAs treated with coil packing of the saccular cavity. Seven BBAs were treated by balloon-assisted coil embolization, while two BBAs were embolized without balloon inflation, though a balloon catheter was on standby at the ICA. Six patients (66.7%) had GOS score of 5 and two (22.2%) had fatal outcomes, GOS score 1. During the follow-up period, two out of seven (28.6%) aneurysms presented with angiographically recurrence and were both treated with saccular coil embolization, the remaining five aneurysms (71.4%) were completely resolved. The authors affirm that treatment should not be focused on the BBA sac alone, but also on the affected wall of the ICA itself. The authors strategy can preserve the ICA flow, though the risks of regrowth and re-bleeding remain. Though embolization itself cannot dispose off the lesion completely, the authors consider that it may temporarily reduce the lesional activity, helping the affected ICA wall to heal spontaneously. As for the treatment time, the authors advocate it might be better to wait until the subacute or chronic phase when the wall of the lesion

becomes more stable and sometimes progresses to a more saccular appearance for coil embolization to be successful, while not overlooking the risk of aneurysm re-rupture.

In 2007 a retrospective study was performed comparing coil embolization with aneurysm trapping and parent vessel occlusion. Seven patients were diagnosed with BBA on the dorsal surface of the ICA with no relation to an arterial branch. Endovascular treatments included seven endosaccular coil embolizations (four conventional, two stent-assisted, and one balloon-assisted procedure) in four patients and five endovascular procedures in which the ICA was trapped in five patients. Complications were procedure-induced ruptures in three cases and acute in stent thrombosis in one case. All follow-up angiograms showed aneurysm regrowth, which included all cases treated with stent and balloon assisted embolization. In all cases of recurrent disease, the aneurysm necks were elongated and coil masses were moved away from the neck. The authors advocate the treatment that focuses only on saccular dilation portions cannot prevent further bleeding or recurrence and explain that trapping of the ICA segment and the aneurysm is a proper treatment when the collateral circulation is intact. They recommend endosaccular coil embolization cannot be the definitive treatment for ICA BBAs cause were observed regrowth/re-bleeding in all cases⁽⁵⁾.

The best advantage of coil embolization of BBAs is that antiplatelet therapy is not needed and balloon-assisted coil embolization for wide-necked BBAs is feasible. However, considering that they are fragile and have a tendency to progress in size over a short period, primary coiling may be dangerous, given the lesion's wide neck, small size and weak wall that lacks collagenous tissue, particularly in the acute period. Despite some selective cases, coil embolization alone is not the optimal approach for treating ruptured BBAs^(5,18-20).

Endovascular stent placement has been reported to be a potentially effective treatment of uncoilable intradural aneurysms⁽²¹⁾. One of these techniques for BBAs treatment include stent-assisted coil embolization. On relevant researches there are good clinical outcomes. In one study this technique is performed in 11 patients and about 80% of their patients had a good clinical outcome. In eight of their cases, there was no aneurysm recurrence. However, stent-assisted coiling of a BBAs has the disadvantage of having to enter the BBAs lumen and the risks of aneurysm rupture⁽¹¹⁾. Another modality is the stent-in-stent, which entails the deployment of two endovascular stents, a longer stent and a shorter one. The longer stent is deployed first, spanning a

large portion of the supraclinoid ICA segment and covering the aneurysm neck. A second, shorter stent is then deployed within the lumen of the longer stent, also spanning the aneurysm neck. Lee et al, 2009⁽²²⁾ presented nine patients diagnosed with BBAs and treated with this technique showing complete resolution with a smooth reconstruction of the affected ICA segment and with a good clinical outcome of all patients. Gaughen et al, 2010⁽⁸⁾ presented a series of six patients diagnosed as ruptured supraclinoid ICA blister aneurysms. All six patients were treated with endovascular stent placement, by using the stent-in-stent technique. These patients were treated with a staged protocol: immediate treatment by using a stent-in-stent technique in an effort to temporize, preserve the artery, and diminish the flow into and hemodynamic stresses placed upon these lesions through flow diversion. The second stage consisted of careful and rapid follow-up with coil embolization of the aneurysms that enlarged. In three patients, the aneurysms did not enlarge, and the stent-in-stent technique was curative. In this cohort, three of six aneurysms enlarged and underwent subsequent coil embolization as part of planned staged procedure. One patient had re-bleeding from a blister aneurysm following overlapping stent deployment, necessitating eventual parent vessel occlusion. The authors expose this approach allows for parent vessel preservation, with a concomitant reduction in the risk of subsequent stroke development. They also argue overlapping stents decrease the flow into these aneurysms, at least to visual inspection on the angiogram.

Other modality of endovascular technique using stents is the monostenting with open-cell stents, which offers the benefit to secure ruptured aneurysms and prevent rebleeding. Often they are used to prevent coil prolapse in wide-necked aneurysms. However, some studies in animal models have demonstrated that open-cell stents could effectively stagnate flow within aneurysm lumens without the introduction of coils⁽²³⁾. In humans some case reports have been published describing this technique with hoping great results⁽⁸⁾. Bulsara et al, 2013⁽²⁴⁾ presented five patients with ruptured BBA, all of them were treated with open-cell self-expanding stents, resulting in total aneurysm occlusion at follow-up and good neurological outcomes. Two complications were observed but with no changes in the neurological status. The authors conclusion was that the advantages of open-cell stents are the availability of long-term complication rates and a better understanding of the optimal antiplatelet regimen required for their safe use. These stents have the advantage of necessitating only single antiplatelet

therapy postoperatively, this is significant in the presence of acute SAH, and open-cell stents have the benefit of offering minimal manipulation of the surrounding anatomy.

A covered stent may be considered for ICA reconstruction with BBA occlusion. In the report of Lee et al, 2009⁽²²⁾, ICA rupture occurred during the procedure in 1 of the 3 who initially underwent treatment with a covered stent, and this patient died as a result. The authors claim, if the second stent insertion is not possible immediately after embolization alone, a very short-term angiographic follow-up is mandatory. If BBA regrowth is detected, covered stent placement, or ICA sacrifice with or without bypass may be considered as possible treatment options depending on the patient's anatomical factors and medical conditions.

BBAs are often located close to the origin of the posterior communicating artery and the anterior choroidal artery, making the use of a covered stent less suitable by the additional risk for vessel wall injury with potentially intraprocedural rupture, thus some authors propose the use of flow-diverting or multiple overlapping (telescopic) stents particularly in these locations, with or without simultaneous coiling^(8,22,25). These authors suggest that the presented devices carry a low risk of obstructing side branches and/or small perforating arteries.

Wagner et al, 2012⁽²⁶⁾ presented a series of 26 wide-necked or blister aneurysms treated with flow-diverting stents and reported an 18% procedural complication rate. Most procedural complications were related to stent thrombosis. The overall mortality rate was about 5%. The use of flow-diverting stents for treating ruptured BBAs is a new strategy for treatment, so antiplatelet therapy after these procedures must be established. Participants of a study included seven patients diagnosed with SAH, flow-diverting treatment was accomplished in all but one patient who was treated by parent artery occlusion (PAO) due to an access problem. Another two patients received stents used telescopically (double stenting). Because of the high risk of thrombosis, flow diverters mandate the use of dual-antiplatelet therapy, which carries additional hemorrhagic risks. Dual antiplatelet treatment was continued for three months (starting from the day after treatment) with clopidogrel and aspirin, and aspirin alone was further continued for the next three months. On the clinical outcome, two patients (28,4%) had modified Rankin Scale (mRS) 0, two patients had mRS 1, and the other three patients had mRS 2, 3 or 4⁽⁶⁾.

Flow diverter devices such as the Pipeline embolization device (PED; Medtronic Neurovascular)

and Silk (Balt Extrusion) for treatment of blister aneurysms is gaining in popularity and has the potential for becoming the standard of care^(1,3,6,27-35). Linfante et al, 2017⁽³²⁾ noted successful deployment of the PED in nine of 10 patients with ruptured blister pathology and an average Hunt and Hess score of 1.6 on presentation. Eight of the nine patients treated with the PED had a 90-day mRS score of 0, and the remaining patient had a score of 1. Chalouhi et al, 2014⁽³⁶⁾ reported complete aneurysm occlusion and an mRS score of ≤ 2 in all eight patients in their series on PED treatment of blister aneurysms. Other smaller case series of the PED for blister pathology have reported complete occlusion of a blister aneurysm and an mRS score of ≤ 2 in all patients^(29,37). Similar results with the SILK device were reported by Aydin et al, 2015⁽²⁷⁾ in 2015, in a retrospective study of 11 patients with ruptured blister aneurysms. Complete occlusion in all patients was achieved at the 6-month follow-up visit, and all had mRS scores of ≤ 2 .

Conclusion

High complication rates associated with surgery have sparked considerable interest in endovascular techniques, though not well-studied, to treat blister aneurysms. Long-term follow-up and experience in larger studies are required to better define the role of endovascular therapy in the management of these difficult lesions.

Emerging from the available endovascular techniques, flow-diverting stents appears to be the safest and most effective treatment modality, with a higher rate of complete occlusion and a lower rate of retreatment. However, delayed aneurysm occlusion and the need for dual antiplatelet therapy are potential drawbacks to flow diversion that must be considered when choosing among treatment methods for BBAs. The development of novel flow-diverting stents with decreased thrombogenic properties, may represents a key step forward and increases the potential for flow diversion becoming the gold standard for endovascular treatment of blister aneurysms.

References

1. Causin F, Pascarella R, Pavesi G, Marasco R, Zambon G, Battaglia R, et al. Acute endovascular treatment (< 48 hours) of uncoilable ruptured aneurysms at non-branching sites using silk flow-diverting devices. *Interv Neuroradiol*. 2011; 17(3):357-64.
2. Meling TR, Sorteberg A, Bakke SJ, Slettebø H, Hernesniemi J, Sorteberg W. Blood blister-like aneurysms of the internal carotid artery trunk causing subarachnoid hemorrhage: treatment and outcome. *J Neurosurg*. 2008; 108(4):662-71.
3. Ogawa A, Suzuki M, Ogasawara K. Aneurysms at nonbran-

- ching sites in the supraclinoid portion of the internal carotid artery: internal carotid artery trunk aneurysms. *Neurosurgery*. 2000; 47(3):578-83; discussion 583-6.
4. Kazumata K, Nakayama N, Nakamura T, Kamiyama H, Terasaka S, Houkin K. Changing treatment strategy from clipping to radial artery graft bypass and parent artery sacrifice in patients with ruptured blister-like internal carotid artery aneurysms. *Neurosurgery*. 2014; (10 Suppl 1):66-72; discussion 73.
 5. Park JH, Park IS, Han DH, Kim SH, Oh CW, Kim JE, et al. Endovascular treatment of blood blister-like aneurysms of the internal carotid artery. *J Neurosurg*. 2007; 106(5):812-9.
 6. Çınar C, Oran İ, Bozkaya H, Ozgiray E. Endovascular treatment of ruptured blister-like aneurysms with special reference to the flow-diverting strategy. *Neuroradiology*. 2013; 55(4):441-7.
 7. Ishikawa T, Nakamura N, Houkin K, Nomura M. Pathological consideration of a "blister-like" aneurysm at the superior wall of the internal carotid artery: case report. *Neurosurgery*. 1997; 40(2):403-5; discussion 405-6.
 8. Gaughen JR, Hasan D, Dumont AS, Jensen ME, McKenzie J, Evans AJ. The efficacy of endovascular stenting in the treatment of supraclinoid internal carotid artery blister aneurysms using a stent-in-stent technique. *AJNR Am J Neuroradiol*. 2010; 31(6):1132-8.
 9. Kalani MY, Zabramski JM, Kim LJ, Chowdhry SA, Mendes GA, Nakaji P, et al. Long-term follow-up of blister aneurysms of the internal carotid artery. *Neurosurgery*. 2013; 73(6):1026-33; discussion 1033.
 10. Kim JH, Kwon TH, Kim JH, Park YK, Chung HS. Internal carotid artery dorsal wall aneurysm with configurational change: Are they all false aneurysms? *Surg Neurol*. 2006; 66(4):441-3; discussion 443.
 11. Meckel S, Singh TP, Undrén P, Ramgren B, Nilsson OG, Phatouros C, et al. Endovascular treatment using predominantly stent-assisted coil embolization and antiplatelet and anticoagulation management of ruptured blood blister-like aneurysms. *AJNR Am J Neuroradiol*. 2011; 32(4):764-71.
 12. Sundt TM Jr, Murphey F. Clip-grafts for aneurysm and small vessel surgery. Clinical experience in intracranial internal carotid artery aneurysms. *J Neurosurg*. 1969; 31(1):59-71.
 13. Mikami Y, Manabe T, Lie JT, Sakurai T, Endo K. Intramural sarcoma of the carotid artery with adventitial inflammation and fibrosis resembling 'inflammatory aneurysm'. *Pathol Int*. 1997; 47(8):569-74.
 14. Shigeta H, Kyoshima K, Nakagawa F, Kobayashi S. Dorsal internal carotid artery aneurysms with special reference to angiographic presentation and surgical management. *Acta Neurochir (Wien)*. 1992; 119(1-4):42-8.
 15. Silva JC, Faquini IV, Kitamura MA, Azevedo-Filho HR. Internal carotid artery blood blister-like aneurysm. *Arq Neuropsiquiatr*. 2008; 66(3A):563-565.
 16. Andaluz N, Zuccarello M. Blister-like aneurysms of the anterior communicating artery: a retrospective review of diagnosis and treatment in five patients. *Neurosurgery*. 2008; 62(4):807-11; discussion 811.
 17. Başkaya MK, Ahmed AS, Ateş O, Niemann D. Surgical treatment of blood blister-like aneurysms of the supraclinoid internal carotid artery with extracranial-intracranial bypass and trapping. *Neurosurg Focus*. 2008; 24(2):E13.
 18. Matsubara N, Miyachi S, Tsukamoto N, Izumi T, Naito T, Haraguchi K, et al. Endovascular coil embolization for saccular-shaped blood blister-like aneurysms of the internal carotid artery. *Acta Neurochir (Wien)*. 2011 Feb; 153(2):287-94.
 19. Ezaki Y, Takahata H, Kamada K, Baba S, Kaminogo M. Aneurysmal embolization of a blisterlike aneurysm of the internal carotid artery: a case report and review of the literature. *Surg Neurol*. 2006; 65(6):628-30; discussion 630.
 20. Tiefeng Ji, Yunbao Guo, Xiuying Huang, Baofeng Xu, Kan Xu, Jinlu Yu. Current status of the treatment of blood blister-like aneurysms of the supraclinoid internal carotid artery: A review. *Int J Med Sci*. 2017; 14(4):390-402.
 21. Fiorella D, Albuquerque FC, Deshmukh VR, Woo HH, Rasmussen PA, Masaryk TJ, et al. Endovascular reconstruction with the Neuroform stent as monotherapy for the treatment of uncoilable intradural pseudoaneurysms. *Neurosurgery*. 2006; 59(2):291-300.
 22. Lee BH, Kim BM, Park MS, Park SI, Chung EC, Suh SH, et al. Reconstructive endovascular treatment of ruptured blood blister-like aneurysms of the internal carotid artery. *J Neurosurg*. 2009; 110(3):431-6.
 23. Wakhloo AK, Tio FO, Lieber BB, Schellhammer F, Graf M, Hopkins LN. Self-expanding nitinol stents in canine vertebral arteries: hemodynamics and tissue response. *AJNR Am J Neuroradiol*. 1995; 16(5):1043-51.
 24. Bulsara KR, Kuzmik GA, Hebert R, Cheung V, Matouk CC, Jabbour P, et al. Stenting as monotherapy for uncoilable intracranial aneurysms. *Neurosurgery*. 2013; 73(1 Suppl Operative):ons80-5; discussion ons85.
 25. Kim BM, Chung EC, Park SI, Choi CS, Won YS. Treatment of blood blister-like aneurysm of the internal carotid artery with stent-assisted coil embolization followed by stent-within-a-stent technique. Case report. *J Neurosurg*. 2007; 107(6):1211-3.
 26. Wagner A, Cortsen M, Hauerberg J, Romner B, Wagner MP. Treatment of intracranial aneurysms. Reconstruction of the parent artery with flow-diverting (Silk) stent. *Neuroradiology*. 2012; 54(7):709-18.
 27. Aydin K, Arat A, Sencer S, Hakyemez B, Barbuoglu M, Sencer A, et al. Treatment of ruptured blood blister-like aneurysms with flow diverter SILK stents. *J Neurointerv Surg*. 2015; 7(3):202-9.
 28. Buyukkaya R, Kocaeli H, Yildirim N, Cebeci H, Erdoğan C, Hakyemez B. Treatment of complex intracranial aneurysms using flow-diverting Silk® stents. An analysis of 32 consecutive patients. *Interv Neuroradiol*. 2014; 20(6):729-35.
 29. Consoli A, Nappini S, Renieri S, Limbucci N, Ricciardi F, Mangiafico S. Treatment of two blood blister-like aneurysms with flow diverter stenting. *J Neurointerv Surg*. 2012; 4:e4.
 30. Kalani MYS, Albuquerque FC, Levitt M, Nakaji P, Spetzler RF, McDougall C. Pipeline embolization for definitive endoluminal reconstruction of blister-type carotid aneurysms after clip wrapping. *J Neurointerv Surg*. 2016; 8(5):495-500.
 31. Lin N, Brouillard AM, Keigher KM, Lopes DK, Binning MJ, Liebman KM et al. Utilization of pipeline embolization device for treatment of ruptured intracranial aneurysms: US multicenter experience. *J Neurointerv Surg*. 2015; 7(11):808-15.
 32. Linfante I, Mayich M, Sonig A, Fujimoto J, Siddiqui A, Dabus G. Flow diversion with pipeline embolic device as treatment of subarachnoid hemorrhage secondary to blister aneurysms: dual-center experience and review of the literature. *J Neurointerv Surg*. 2017; 9(1):29-33.
 33. Malatesta E, Nuzzi NP, Divenuto I, Fossaceca R, Lombardi M, Cerini P, et al. Endovascular treatment of intracranial aneurysms with flow-diverter stents: preliminary single-centre experience. *Radiol Med*. 2013; 118(6):971-83.
 34. Mazur MD, Taussky P, MacDonald JD, Park MS. Rupture of a blister aneurysm after treatment with a single flowdiverting stent. *Neurosurgery*. 2016; 79(5):E634-E638.
 35. Nerva JD, Morton RP, Levitt MR, Osburn JW, Ferreira MJ, Ghodke BV, et al. Pipeline Embolization Device as primary treatment for blister aneurysms and iatrogenic pseudoaneurysms of the internal carotid artery. *J Neurointerv Surg*. 2015; 7(3):210-6.

36. Chalouhi N, Zanaty M, Tjoumakaris S, Gonzalez LF, Hasan D, Kung D, et al. Treatment of blister-like aneurysms with the pipeline embolization device. *Neurosurgery* 2014; 74(5):527–32.
37. Hu YC, Chugh C, Mehta H, Stiefel MF. Early angiographic occlusion of ruptured blister aneurysms of the internal carotid

artery using the pipeline embolization device as a primary treatment option. *J Neurointerv Surg*. 2014; 6(10):740–3.

Trabalho recebido: 05/06/2018
Trabalho aprovado: 04/10/2018
Trabalho publicado: 10/12/2018