

# Cerebral proliferative angiopathy: a review

## Angiopatia proliferativa cerebral: uma revisão

André Freitas Nunes<sup>1</sup>, Rafael Gomes dos Santos<sup>1</sup>, Rodrigo Salmeron de Toledo Aguiar<sup>1</sup>,  
José Carlos Esteves Veiga<sup>2</sup>, Heitor Castelo Branco Rodrigues Alves<sup>3</sup>, Mario Luiz Marques Conti<sup>4</sup>,  
Guilherme Brasileiro de Aguiar<sup>5</sup>

### Abstract

**Introduction:** Cerebral Arteriovenous Malformations (AVMs) are vascular lesions defined by arteriovenous shunting flowing through a nidus of coiled and tortuous vascular connections. Cerebral Proliferative Angiopathy (CPA) is a rare type of AVM with pathological, clinical, diagnostic features and treatment differences from a typical AVM. We aimed to summarize important features of CPA already described and identify important gaps of evidence.

**Methods:** Data was selected by a search of PUBMED with the term "cerebral proliferative angiopathy". The articles considered relevant were included in this review. We also screened article references and included them as needed.

**Discussion:** CPA shows a diffuse nidus appearance, presence of transdural supply and stenosis of feeding arteries, without dominant feeders or flow-related aneurysms. There is intermingled brain between the vascular spaces. The usual clinical presentation is seizures, headaches, and progressive neurological deficits. Sound diagnosis can be made based on CT, MRI, Angiography and perfusion techniques, which are essential to treatment choices. Invasive treatment is seldom indicated, in order to preserve the normal brain parenchyma, and clinical control of symptoms, associated with a

thorough follow-up, is the usual approach in most reported cases. **Conclusion:** Still much remains to be learned about CPA. Establishing more precise roles of various radiological assessing methods, how they affect the follow-up of patients, and safety and efficacy profiles of different treatment approaches will provide us the tools to give patients a more solid intervention and clearer follow-up.

**Keywords:** Vascular malformations, Intracranial arteriovenous malformations, Brain diseases, Cerebrovascular disorders

### Resumo

**Introdução:** As malformações arteriovenosas cerebrais (MAVs) são lesões vasculares definidas por comunicação arteriovenosa por meio de conexões vasculares tortuosas. A angiopatia cerebral proliferativa (ACP) é um tipo raro de MAV com características patológicas, clínicas, diagnósticas e de tratamento distintas das MAVs típicas. Objetivou-se resumir características importantes da ACP já descritas na literatura, e identificar lacunas importantes nas evidências.

**Métodos:** Os dados foram selecionados através de busca na base de dados PUBMED, com o termo "cerebral proliferative angiopathy". Os artigos considerados relevantes foram incluídos nessa revisão, assim como alguns outros artigos presentes nas referências. **Discussão:** A ACP apresenta-se como um nidus difuso, associada à presença de irrigação transdural, de estenose das artérias que a alimentam, sem suprimento arterial dominante ou aneurismas relacionados ao fluxo. Há parênquima cerebral normal entre os espaços vasculares. Comumente se apresenta com crises epilêpticas, cefaleia e déficits neurológicos progressivos. O diagnóstico de certeza pode ser realizado através de TC, RM, angiografia e técnicas de perfusão, e é essencial para a escolha do tratamento. Abordagens invasivas são raramente indicadas a fim de preservar o parênquima cerebral normal. O controle clínico dos sintomas, associado a seguimento rigoroso, é a escolha terapêutica geralmente utilizada na maioria dos relatos. **Conclusão:** Ainda há muito que se aprender sobre a ACP. Estabelecer os benefícios de cada um dos diversos métodos imaginológicos, como eles influenciam o seguimento dos pacientes, e perfis de segurança e eficácia das

1. Neurosurgery Resident at Santa Casa de Sao Paulo. Department of Surgery. São Paulo – SP - Brazil

2. Full Professor at Santa Casa de Sao Paulo School of Medical Sciences. Department of Surgery. São Paulo – SP - Brazil

3. Neuroradiologist at Santa Casa de Sao Paulo. Department of Surgery – São Paulo – SP - Brazil

4. Assistant Professor at Santa Casa de Sao Paulo School of Medical Sciences. Department of Surgery. São Paulo – SP - Brazil

5. Instructor Professor at Santa Casa de Sao Paulo School of Medical Sciences. Department of Surgery. São Paulo – SP - Brazil

**Institution:** Santa Casa de Sao Paulo. Department of Surgery. Discipline of Neurosurgery. São Paulo – SP - Brazil

**Correspondence address:** Guilherme Brasileiro de Aguiar. Santa Casa de Sao Paulo School of Medical Sciences - Department of Surgery. Discipline of Neurosurgery. Street: Dr. Cesário Motta Júnior, 61 - Vila Buarque – 01221-020 – São Paulo – SP - Brasil. Telephone: (11) 3367-7700.

All authors of this article declare that there is no conflict of interest in the preparation of this article.

*diferentes terapêuticas fornecerá ferramentas para melhor decisão terapêutica.*

**Descritores:** *Malformações vasculares, Malformações arteriovenosas intracranianas, encefalopatias, Transtornos cerebrovasculares*

## Introduction

Brain arteriovenous malformations (AVMs) are vascular lesions defined by arteriovenous shunting flowing through a nidus of coiled and tortuous vascular connections that link feeding arteries to draining veins. AVMs mostly affect young patients, aged 20–40 years, and have an estimated prevalence of 0,01–0,5% in the general population. They are associated with important morbidity and mortality after rupture. Usually, these lesions present as intracranial hemorrhage. The main treatment goal is to achieve complete obliteration of the malformation, confirmed with angiography, while keeping associated risks to a minimum. Usually, the approach involves microsurgery, endovascular embolization, or radiosurgery<sup>(1)</sup>.

Conversely, cerebral proliferative angiopathy (CPA) is an AVM type that stands apart from others lesions due to its unique angioarchitecture, clinical presentation, and treatment goals. Described as a non-focal angiogenic activity forming a diffuse nidus with intermingled normal brain parenchyma, it composes 2,4% of all brain MAVs<sup>(2)</sup>, and usually, these lesions present as headache and seizures, not with haemorrhages. Treatment is mostly conservative, due to the ischemic nature of the symptoms and risk to harm normal neurological tissue with intervention.

The aim of this article is to carry out a literature review on cerebral proliferative angiopathy with emphasis on its main treatment modalities.

## Method

The authors performed a review of available data regarding cerebral proliferative angiopathy. Search was conducted via Pubmed database with “cerebral proliferative angiopathy” as keyword in the title with 26 articles found, without period restriction. The articles considered relevant were included in this review, especially those that focused on essential aspects of this specific vascular malformation. We also screened article references for further relevant data. A statistical approach could not be conducted due to paucity of data, and therefore a descriptive summary was performed.

## Discussion

Cerebral proliferative angiopathy is a vascular lesion characterized by non-focal angiogenic activity and presence of intermingled brain between the vascular spaces<sup>(1)</sup>. Due to pathophysiological, morphological, clinical and treatment differences, it is regarded as distinct from usual brain arteriovenous malformations (AVMs) — arteriovenous shunting through a nidus of coiled and tortuous vascular connections without an intervening capillary bed<sup>(2-3)</sup>.

According to Lasjaunias et al, 2008<sup>(2)</sup> this clinical entity was delineated by Chin\* et al in 1992. He described a series of 12 cases presenting with a distinct histological and angiographic picture: normal brain parenchyma interspersed with vascular channels, described as “diffuse nidus” AVM<sup>(2)</sup>.

Further MRI findings in a large series of 49 cases retrospectively identified by Lasjaunias et al<sup>(2)</sup>, in 2008, lead to a better understanding of what individualizes CPA: the non-focal angiogenic activity is evident by the presence of transdural supply and feeding arteries stenosis; there is absence of dominant feeders to a large nidus, often of lobar or even hemispheric distribution; the small size of draining veins in relation to arteriovenous shunting zone size is prominent; and the already identified presence of intermingled brain between the vascular spaces, largely different from usual AVMs, whose parenchyma is usually reported as absent or highly gliotic and nonfunctional<sup>(2)</sup>.

From a physiopathological standpoint, angiogenesis might be increased due to markedly elevated levels of vascular endothelial growth factor (VEGF) and other stimulators of angiogenesis, as demonstrated by Marks, Steinberg(2012)<sup>(4)</sup>, in a case report. Thus it lies between the 2 major types of vascular lesions in the biological classification in childhood and infancy by Mulliken and Glowacki — lesions with cellular proliferation and endothelial hyperplasia (hemangiomas), and lesions with normal endothelia turnover but with true structural channel abnormalities (AVMs)<sup>(2)</sup>. CPA corresponded to 3,4% in a series of 1434 patients with AVMs<sup>(1)</sup>. It affects mainly young females (67%, mean age 22 years, range 7–78 years)<sup>(2,5)</sup>.

## Clinical Course

The most common presenting symptoms of CPA are seizures and intense headaches, not related to hemorrhagic events<sup>(1)</sup>. Transitory ischemic attacks, loss of consciousness or progressive neurological

\*Chin et al (1992) APUD Lasjaunias PL, Landrieu P, Rodesch G, Alvarez H, Ozanne A, Holmin S, et al. Cerebral proliferative angiopathy: clinical and angiographic description of an entity different from cerebral AVMs. Stroke. 2008; 39(3):878–85.<sup>(2)</sup>

Table 1

## Treatment choices and follow-up outcomes seen across case reports and series of Cerebral Proliferative Angiopathy.

<i>Study, year [Ref.]</i>	<i>No of cases</i>	<i>Age/Sex</i>	<i>Invasive Treatment</i>	<i>Follow-up (time)</i>
Lasjaunias et al, 2008 <sup>(2)</sup>	49	Mean 22y/ Female (n=33)	Embolization (2)	-
Eesa et al, 2009 <sup>(6)</sup>	1	31/M	-	-
Fierstra et al, 2011 <sup>(15)</sup>	4	F/21 M/23 M/11 F/11	No	-
Marks, 2011 <sup>(4)</sup>	1	30/F	Partial embolization (after worsening)	Before treatment: Progression of angiographic findings (2 yrs) After treatment: recurrence (weeks)
Maekawa et al, 2012 <sup>(7)</sup>	1	62/F	No	Clinical without imaging progression First hemorrhage fatal (7 yrs)
Saliou et al, 2013 <sup>(3)</sup>	12	mean 27,2y/ Females (n=7)	Partial invasive treatment (7)	-
Vargas et al, 2013 <sup>(11)</sup>	3	F/17 F/37 M/14	-	-
Gold et al, 2013 <sup>(8)</sup>	1	9/F	No	Spontaneous resolution with multiple recurrences
Kimiwada et al, 2013 <sup>(21)</sup>	1	13/M	No	Improvement (1 yr)
Van Heerden et al, 2013 <sup>(23)</sup>	1	39/F	-	-
Srivastava et al, 2013 <sup>(9)</sup>	1	18/M	No	Improvement
Khan et al, 2013 <sup>(25)</sup>	1	16/F	No	-
Kono et al, 2014 <sup>(18)</sup>	1	28/M	No	Clinical and imaging progression (1 yr)
Biasi et al, 2015 <sup>(17)</sup>	1	27/F	Partial embolization	Persistence of left hemiparesis (5 yrs)
Kumar et al, 2015 <sup>(10)</sup>	1	23/F	No	Improvement (6 m)
Rohit et al, 2015 <sup>(5)</sup>	1	78/F	No	-
Kumar et al, 2015 <sup>(10)</sup>	1	66/M	No	Total improvement (1 yr)
Liu et al, 2016 <sup>(21)</sup>	5	range 4-52y/ Females (n=3)	EDAS (1)	Clinical improvement with EDAS (1) Stability without intervention (1) Worsening of symptoms (2) Radiological progression (1)
Lopci et al, 2016 <sup>(24)</sup>	1	55/F	Radiation	Clinical and radiological response
Bilaj et al, 2016 <sup>(11)</sup>	1	24/M	Fronto-temporal craniotomy	Recurrent hemorrhage
Puerta et al, 2017 <sup>(22)</sup>	1	8/M	Pial synangiosis and encephalomyosynangiosis Lumbar-peritoneal shunt	Resolution of papilledema (1 m); Persistence of other symptoms (1 yr).
Karian et al, 2017 <sup>(12)</sup>	1	7/M	No	-
Gatto et al, 2018 <sup>(13)</sup>	1	15/F	Embolization	Worsening of cognition and dysarthria
Giragani et al, 2018 <sup>(14)</sup>	1	12/M	-	-

deficits, including speech and gait abnormalities, are also commonly seen across case reports<sup>(6-13)</sup>. Acute neurological deficit or hemorrhage are reported, but are not the usual presentation<sup>(3,7,11,14)</sup>.

Previous radiological findings postulate that the low risk of hemorrhage might be due to decreased intranidal blood pressure, related to proximal artery stenosis and longer mean time transit (MTT) — time that red blood cells spend within a determinate volume of capillary circulation. The usual absence of flow-related aneurysms might also contribute to this “protective” effect<sup>(3)</sup>.

However, when hemorrhage does happen, prognosis highly depends on the location, with one death reported in consequence of infratentorial hemorrhagic episode<sup>(7)</sup>. Moreover, the risk of rebleeding is markedly elevated (67%)<sup>(2,11)</sup>.

Raised intracranial pressure was reported as well. This complication was seen in 3 case reports, 2 presenting with papilledema and one with hydrocephalus<sup>(15-17)</sup>. The clinical course is believed to be less aggressive than true AVMs. Symptoms usually relapse and remit over a few years, and might culminate with a more severe disturbance that motivates an emergency investigation or progresses to significantly impair the patients’s quality of life<sup>(4,8,18)</sup>. However, Marks et al, 2011<sup>(4)</sup>, reported a more rapid progression.

## Diagnosis

Diagnosis can be made by Magnetic Resonance Imaging (MRI) or Computer Tomography (CT), with no demonstrated superiority of any method. They may

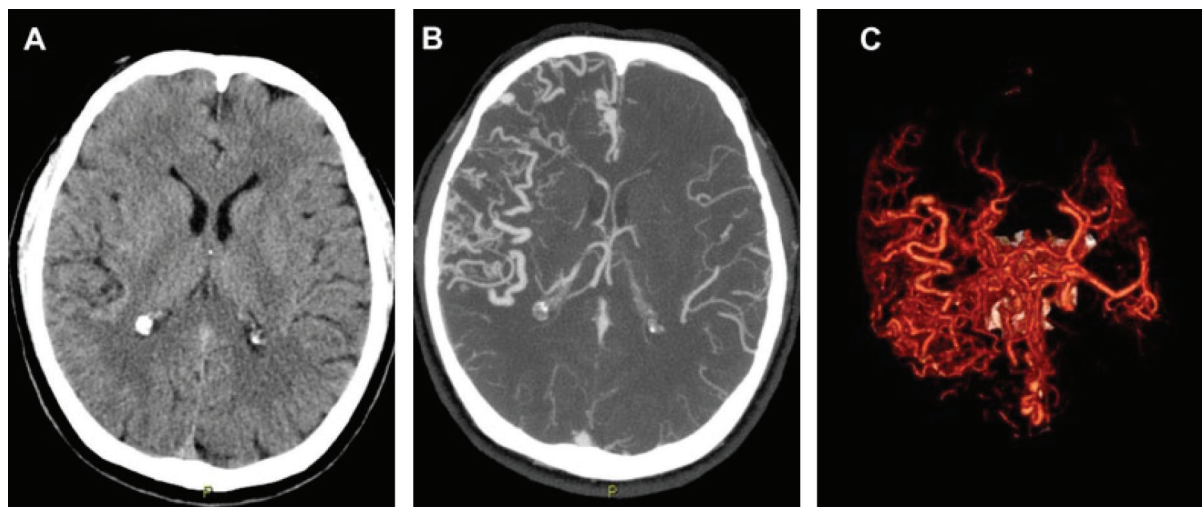
detect the hallmarks of CPA, and are usually enough for differential diagnosis with typical AVMs.

A diffuse network of densely enhancing vascular spaces with intermingled normal brain parenchyma might be considered an essential finding across series of cases and case reports to emit a diagnosis of CPA<sup>(2-25)</sup> (Figure 1). Lesions are usually large and profound, compromising multiple lobes, whole hemispheres or even both sides of the brain, with extension to basal ganglia and thalamus in 85% of cases, and with possible infratentorial impairment<sup>(2,7,10,14,19)</sup>.

Other findings are the paucity of draining vessels compared with the nidus size, proliferation of pial vessels, and presence of flow void — indicating vigorously flowing blood. The absence of acute infarcts or intracranial hemorrhages also supports this diagnosis, even though they can be present<sup>(2,7,10,14,19)</sup>.

Another diagnosis mainstay is remote and widespread hypoperfusion, without evidence of acute ischemia on diffusion-weighted MRI<sup>(6)</sup>. Perfusion images may play a role in the diagnosis and follow-up of these patients, to assess the extension of ischemic compromise and the efficacy of treatments<sup>(3,20)</sup>. Several methods were used across case reports and series, such as perfusion-weighted MRI (PW-MRI)<sup>(3,6,15,20-22)</sup>, 123I-IMP-SPECT<sup>(21)</sup>, 99mTc-ECD-SPECT<sup>(18)</sup>, Positron Emission Tomography (PET)<sup>(23)</sup>, and 11C-METH PET<sup>(24)</sup>.

PW-MRI shows microvascular leakage (MVL) increase, which is associated with angiogenesis — this high contrast extravasation is reflected in an increase in cerebral blood volume (CBV). The mean time transit (MTT) is prolonged and higher than in classical AVMs, probably due to arterial stenosis and



**Figure 1:** Non-contrast computed tomography (A) in a 56-years-old male with headaches and transitory ischemic attacks shows only vessels increased in size and number on the right Sylvian fissure. Computed tomography angiography maximum intensity projection (B) and volume rendering (C) demonstrates a diffuse network of vascular structures throughout the right frontal lobe. There is also paucity of draining veins and dominant feeders compared to the size of the nidus.

the absence of a high flow shunt<sup>(3)</sup>. Cerebrovascular reserve (CVR), a surrogate measure of adequate blood supply, can be severely impaired around the lesions<sup>(15)</sup>. Cerebral blood flow (CBF) is believed to be inaccurately elevated due to increased and abnormal vessel structure, with reports that it is actually reduced on 123I-IMP-SPECT analysis<sup>(21)</sup>. Other methods have shown similar results in publications by different authors<sup>(18, 23- 24)</sup>.

Nevertheless, angiography still remains the golden standard for such lesions. They lack dominant feeders, receiving blood flow from multiple arteries and coil into a diffuse and poorly defined nidus, usually larger than 6 cm (Figure 2). This consistently produces a scattered “puddling” of contrast which persists in the late arterial and early venous phases within what seems to be like capillary ectasias<sup>(2)</sup>.

Stenosis of proximal arteries seems to be present around 39% of cases<sup>(2)</sup>. High-flow arteriovenous fistulous aspects and flow-related aneurysms are usually absent. Nonetheless, this seems to positively correlate with the presence of stenosis.

The “proliferative” aspect of the disease is also demonstrated by angiogenesis remote from the affected zone and the presence of transdural supply in 59% of cases and thoroughly reported in most of case reports<sup>(2-3)</sup>.

Of note, most of these lesions are described at a discrete point in time. Few reports have addressed the imaging evolution of CPA. There is a description of stability on angiography for over 7 years, despite clinical progression<sup>(7)</sup>; a densification of the nidus related to progressive neurological deficits<sup>(18)</sup>; a rapid progression of the angiographic and clinical findings<sup>(4)</sup>; a marked reduction in hypervascularization after radiotherapy<sup>(24)</sup>; and a slight improvement of hypoperfusion after an invasive procedure such as encephaloduroarteriosynangiosis (EDAS)<sup>(18)</sup>. The

specific roles of different imaging modalities on follow-up and their usefulness in maintaining follow-up and establishing prognosis are still to be assessed.

## Treatment

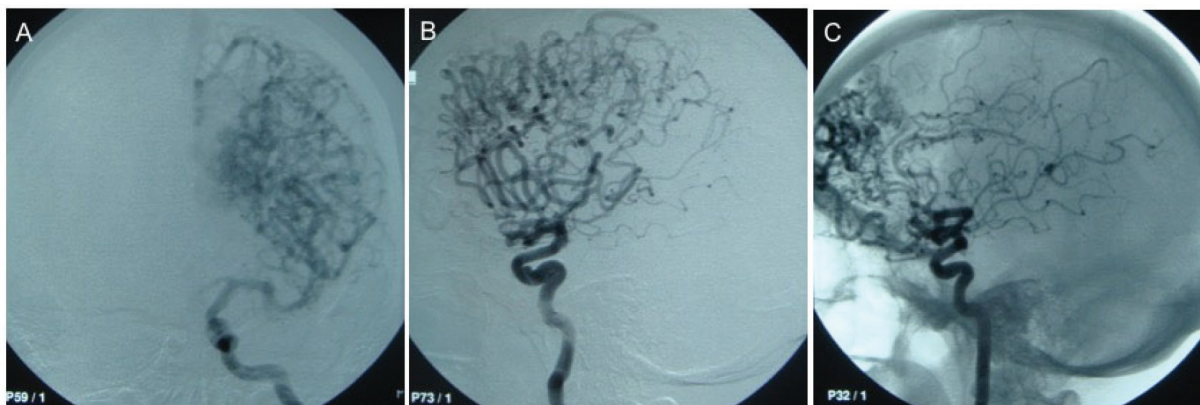It is important to establish a sound diagnosis of CPA due to serious implications regarding treatment options. Whereas typical AVMs are sometimes managed invasively, CPA demands a more conservative approach, mainly because normal brain parenchyma is present among the vessels in a way that surgery and radiosurgery carry the risk of worsening neurological compromise<sup>(2)</sup>.

Antiepileptics and headache medications are widely used, with no clear benefit of one over the other. Although improvement was seen across case reports, we cannot establish how well these medications control symptoms or if they have spontaneous resolution<sup>(12)</sup>.

Other conservative treatments such as acetazolamide for raised intracranial pressure (ICP) and bevacizumab for antiangiogenic purposes have been tried. Acetazolamide achieved ICP in one case report<sup>(10)</sup>, whereas bevacizumab had no impact on the vascular lesion after 4 cycles<sup>(4)</sup>.

According to the literature, invasive treatment was mainly used in the presence of hemorrhages, identifiable fragile angioarchitecture allowing for targeted treatment and refractory symptoms without any other feasible therapeutic measure with varying methods and results<sup>(2)</sup>.

When hemorrhage is the target, partial embolization seems to be sufficient. Partial targeted embolization was employed and yielded progressive improvement in the case reported by Giragani et al, 2018, where the source of bleeding could be clearly identified<sup>(14)</sup> and also in a case series by Lasjaunias et al, 2008<sup>(2)</sup>.



**Figure 2:** Cerebral angiography showing (A – left internal carotid artery / frontal view; B - left internal carotid artery / lateral view; C - right internal carotid artery / lateral view without subtraction) a diffuse network of vascular structures throughout the left frontal lobe, with multiple feeders, without a dominant one.

Conversely, the same procedure aimed at reducing the shunt vascularity lead to symptom recurrence and neurological decline<sup>(3)</sup>. Even when carefully selected, patients carry a risk of ischemic complications because healthy tissue might be embolized.

There is widespread consensus that cortical blood supply enhancement is a rational approach in a subset of patients presenting with poor transdural supply, evident ischemic abnormalities and persisting symptoms during follow-up. Approaches such as skull burr-hole<sup>(2)</sup>, pial synangiosis<sup>(22)</sup> and encephalomyosynangiosis, and encephalo-duroarterio-synangiosis (EDAS)<sup>(18)</sup> have been reported, all with good outcomes.

## Conclusion

Still much remains to be learned about these vascular lesions characterized by non-focal angiogenic activity and presence of intermingled brain between the vascular spaces that we name “cerebral proliferative angiopathy”. Establishing more precise roles of various radiological assessing methods, and how they affect the follow-up of patients with this condition seems necessary. Also, as the evidences related to this rare disease grows, the safety and efficacy profiles of different treatment approaches will become clearer, and patients will benefit more not only from establishing a correct diagnosis of CPA apart from usual MAVs, but also a more effective intervention.

## References

1. Fleetwood IG, Steinberg GK. Arteriovenous malformations. *Lancet*. 2002; 359(9309):863-73.
2. Lasjaunias PL, Landrieu P, Rodesch G, Alvarez H, Ozanne A, Holmin S, et al. Cerebral proliferative angiopathy: clinical and angiographic description of an entity different from cerebral AVMs. *Stroke*. 2008; 39(3):878-85.
3. Saliou G, Krings T, Rutgers DR, Toulgoat F, Ozanne A, Lasjaunias P, et al. PWI-MRI and contrast extravasation in brain AVM help to estimate angiogenic activity. *Neuroradiology*. 2011; 53(10):793-800.
4. Marks MP, Steinberg GK. Cerebral proliferative angiopathy. *J Neurointerv Surg*. 2012; 4:e25.
5. Rohit PSG. Diffuse proliferative cerebral angiopathy: a case report and review of the literature. *J Radiol Case Rep*. 2015; 9(9):1-10.
6. Eesa M, Sharma P, Goyal M. Cerebral proliferative angiopathy. *Can J Neurol Sci*. 2009; 36(2):242-3.
7. Maekawa H, Tanaka M, Hadeishi H. Fatal hemorrhage in cerebral proliferative angiopathy. *Interv Neuroradiol*. 2012; 18(3):309-13.
8. Gold JJ, Crawford JR. Acute hemiparesis in a child as a presenting symptom of hemispheric cerebral proliferative angiopathy. *Case Rep Neurol Med*. 2013; 2013:920859.
9. Srivastava T, Jain TMR, Sannegowda RB. Cerebral proliferative angiopathy: A rare clinical entity with peculiar angiographic features. *Ann Indian Acad Neurol*. 2013; 16(4):674-5.
10. Kumar S, Srivastava T, Tejwani S, Khilnani K. Cerebral proliferative angiopathy with papilledema. *Clin Neurol Neurosurg*. 2015; 139:12-5.
11. Bilaj F, Rroju A, Enesi E, Ruka M, Petrela M. Cerebral proliferative angiopathy with tumor-like hemorrhage: A case report and literature review. *Neuroradiol J*. 2016; 29(5):336-9.
12. Karian V, Rabner J, LeBel A. Cerebral proliferative angiopathy. *Pediatr Neurol*. 2017; 66:115-6.
13. Gatto LAM, Brisson RT, Demartini Z, Kope G, Rocha Jr C. Cerebral proliferative angiopathy: case report. *Arq Bras Neurocir*. 2018; 37(2):131-3.
14. Giragani S, Pavunesan SK, Balasubramaniam A. Targeted endovascular treatment of haemorrhagic posterior fossa proliferative angiopathy. *Interv Neuroradiol*. 2018; 24(4):440-3.
15. Fierstra J, Spieth S, Tran L, Conklin J, Tymianski M, ter Brugge KG, et al. Severely impaired cerebrovascular reserve in patients with cerebral proliferative angiopathy. *J Neurosurg Pediatr*. 2011; 8(3):310-5.
16. Van Heerden J, Cheung A, Phatouros CC. A rare case of cerebral proliferative angiopathy with bihemispheric morphology. *Neurol Clin Pract*. 2013; 3(3):266-9.
17. Biasi PR, Almeida TAL, Espanhol RA, Brunet MP, Crusius PS, Mallmann AB, et al. Cerebral proliferative angiopathy - description of a rare clinical entity. *Arq Bras Neurocir*. 2015; 34(1):82-5.
18. Kono K, Terada T. Encephaloduroarteriosynangiosis for cerebral proliferative angiopathy with cerebral ischemia. *J Neurosurg*. 2014; 121(6):1411-5.
19. Kumar S, Sharma M, Srivastava T, Sinha VD. Infratentorial hemorrhagic cerebral proliferative angiopathy: a rare presentation of a rare disease. *Asian J Neurosurg*. 2015; 10(3):240-2.
20. Vargas MC, Castillo, M. Magnetic resonance perfusion imaging in proliferative cerebral angiopathy. *J Comput Assist Tomogr*. 2011; 35(1):33-8.
21. Kimiwada T, Hayashi T, Shirane R, Tominaga T. 123I-IMP-SPECT in a patient with cerebral proliferative angiopathy: a case report. *J Stroke Cerebrovasc Dis*. 2013; 22(8):1432-5.
22. Puerta P, Guillén A, Muchart J, González V, Ferrer E. Cerebral proliferative angiopathy in a child. *Pediatr Neurosurg*. 2017; 52(3):214-6.
23. Liu P, Lv X, Lv M, Li Y. Cerebral proliferative angiopathy: clinical, angiographic features and literature review. *Interv Neuroradiol*. 2016; 22(1):101-7.
24. Lopci E, Olivari L, Bello L, Navarra P, Chiti A. Cerebral Proliferative Angiopathy (CPA): imaging findings and response to therapy. *Clin Nucl Med*. 2016; 41(12): e527-e529.
25. Khan A, Rattihalli R, Beri S, Dickinson F, Hussain N, Gosalakal J. Cerebral proliferative angiopathy: a rare form of vascular malformation. *J Paediatr Child Health*. 2013; 49(6):504-8.

Trabalho recebido: 29/08/2018

Trabalho aprovado: 26/04/2019

Trabalho publicado: 30/04/2019