

Residents position volar plate evaluation for the fractures of the distal radius

Avaliação do posicionamento da placa volar para fraturas do rádio distal

Leandro Viecili¹, Antonio Carlos da Costa¹, Diego Figueira Falcochio¹,
Valdênia das Graças Nascimento¹, Ivan Chakkour¹

Abstract

Background: At the end of the residency, the orthopedic surgeon will have access to other types of plate's osteosynthesys for treating distal radius fractures that may be unknown to them. The aim was to assess and compare the outcomes from positioning the plate on the volar surface of the radius obtained by residents at the Department of Orthopedics and Trauma. **Methods:** Cross-sectional study at public hospital. Thirty positions were analysed, performed by residents, of blocked volar plates in a cadaveric left radius prepared with a simulated simple distal metaphyseal fracture. **Results:** 17 plate positioning (56.66%) were correct and, among these, the average distance between the end of the plate and the watershed line was +0.91 mm distal to it; the average proximal coronal positioning of the plate was 0.69 mm radial to the midline of the radius; and the average distance between the plate and the bone surface in the sagittal plane was 0.97 mm. **Conclusions:** Slightly more than half of residents correctly identified the plate's laterality. There was a statistically significant correlation between the plate-bone distances, in the sagittal plane, and between the plate's distal end and the watershed line, in the coronal plane.

Keywords: Radius fractures; Orthopedics; Surgical procedures, operative; Radius; Orthopedic procedures

Resumo

Objetivo: Ao término da residência, o ortopedista terá acesso a outros tipos de placas muitas vezes desconhecidas por ele. O objetivo foi avaliar e comparar os resultados do posicionamento da placa na superfície volar do rádio entre os residentes dos três anos de Ortopedia e Traumatologia deste departamento. **Métodos:** Estudo transversal realizado em um hospital público. Foram analisados trinta posicionamentos, realizados por residentes, de placas volares bloqueadas em um rádio esquerdo preparado de cadáver com fratura simples metafisária distal simulada. **Resultados:** Houveram 17 (56,66%) posicionamentos corretos da placa e, destes, a distância média entre o final da placa à linha divisora de águas foi de +0,91 mm distal a esta; a média do posicionamento coronal proximal da placa foi de 0,69 mm radial à linha média do rádio; e a média da distância entre a placa e a superfície óssea no plano sagital foi de 0,97 mm. Houve correlação de significância estatística entre as distâncias placa-osso no plano sagital e da linha divisora de águas ao limite distal da placa no plano coronal. **Conclusões:** Pouco mais da metade dos residentes identificou corretamente a lateralidade da placa. Existe relação entre as distâncias placa-osso no plano sagital e entre o limite distal da placa e a linha divisora de águas, no plano coronal.

Palavras Chave: Fraturas do rádio, Ortopedia; Procedimentos cirúrgicos operatórios, Rádio (Anatomia), Procedimentos ortopédicos

Introduction

Fractures of the distal radius are among the most common fractures affecting the human body, with functional and socioeconomic consequences that are known to be significantly important⁽¹⁻³⁾. They are the most frequent fractures of the upper limb, representing one sixth of all fractures in patients over 50 years of age⁽⁴⁾. In the literature, there is not one single treatment method that is effective for all types of fractures^(4,5). Among the treatment methods described are plaster

1. Santa Casa de Sao Paulo School of Medical Sciences. Department of Orthopedics and Traumatology. São Paulo – SP – Brazil

Institution: Santa Casa de Sao Paulo School of Medical Sciences. Department of Orthopedics and Traumatology. Pavilhão Fernandinho Simonsen. São Paulo – SP – Brazil

Correspondence address: Leandro Viecili. Rua Major Sertório, 321 - Apto 233 - Vila Buarque – 01222-001 - São Paulo - SP - Brasil. E-mail: leandro.viecili@hotmail.com

Conflict of Interest Statement: The authors declare that they have no conflict of interest.

Statement of Informed Consent: Informed consent was obtained from all individual participants included in the study.

Statement of Human and Animal Rights: All procedures followed were in accordance with the ethical standards of the responsible committee on human experimentation (institutional and national) and with the Helsinki Declaration of 1975, as revised in 2008 (5). Informed consent was obtained from all patients for being included in the study.

Statement of Funding: None

cast immobilization, percutaneous Kirschner wires, dorsal plates, volar plates and external fixation⁽⁶⁻⁹⁾.

The volar surgical approach and the use of locked plates have a considerable biomechanical advantage and lower risk of tendon complications when compared to dorsal plates⁽¹⁰⁾.

The fixed-angle locked plate revolutionized the treatment of these fractures over the last decade, and due to its angular stability, the distal screws stabilize the system by forming a sort of rake, whose teeth maintain the stability of the articular component⁽¹¹⁾. Consequently, not only did the method's popularity increase, but also the number of implants commercially available⁽¹²⁾, as well as the number of complications⁽¹³⁾.

In 2006, Orbay, Touhami⁽¹⁴⁾ reported that the volar face of the radius has a concave profile in the coronal plane corresponding to the fossa of the pronator quadratus muscle, whose distal end is the watershed line as shown in Figure 1 where we note the volar surface of the distal end of the right radius following total removal of soft tissues: the dotted red line indicates the distal margin of the pronator quadratus muscle; the red and blue dots indicate the medial and lateral prominences, respectively; the dotted blue line indicates the connection of distal bony demarcation points; the dotted yellow line indicates the connection of proximal bony demarcation points; the dotted green line indicates the connection of radial bony demarcation points and the watershed line is the continuation from the green line to the blue line.

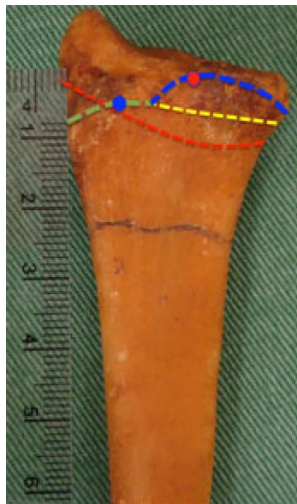


Figure 1. Volar surface of the distal end of the right radius following total removal of soft tissues. The watershed line is the continuation from the green line to the blue line.

The plates, being increasingly designed to adapt and fit to the watershed line projections, would minimize tendon attrition when placed proximally

in relation to that line⁽¹⁵⁻¹⁷⁾. The reduced number of reports of such bony prominence in the literature is noteworthy^(14,17).

Most of Brazil's medicine residency programs are linked to the so-called "Sistema Único de Saúde" ("SUS" - the National Health System), which precludes the use of modern plate osteosynthesis techniques for treating distal third radius fractures. Nevertheless, by the time the orthopedists finish their residency, they will have access to other types of plates that, in many cases, may be unknown to them. Despite the increased popularity of the volar access method for treating fractures of the distal radius, the surgeon's lack of experience may result in difficulties in appropriately positioning the plate and consequently, which may thus lead to undesirable consequences⁽¹⁸⁾.

The purpose of the current study is to assess the positioning of the plate on the radius, and to compare the outcomes obtained by first-, second- and third-year residents at the Department of Orthopedics and Trauma.

Methods

Thirty residents at the Department of Orthopedics and Trauma at a medical school were divided into three groups comprised of 10 members each: first-year residents (Group R1), second-year residents (Group R2), and third-year residents (Group R3).

The left radius of a corpse, dissected and varnished, was used; it was provided by the Department of Morphology at the same institution. With the aid of a common graphite pencil, the trace of a simple metaphyseal fracture was simulated. Two variable angle locked double-row volar plates from Synthes® (Synthes Indústria e Comércio Ltda./Synthes GmbH, Switzerland) were used: one to the right and one to the left side, with the plate's orientation occulted by an adhesive tape.

In a calm environment and in front of a green background table containing the radio and the two plates (Figure 2), the residents were given the following guidelines in writing: "Taking into consideration the anatomical parameters of the distal end of the radius and the fracture trace shown, position one of the plates given in the correct way and fix it with adhesive tape."

Two photographs per resident were taken: one in the coronal plane, and one in the sagittal plane, totaling altogether 60 images.

Assessment of plate positioning was conducted with digitalized images, considering the plate's laterality. In those situations where the correct plate, i.e. the left one, was selected, we studied: the advancement (positive value) or retraction (negative

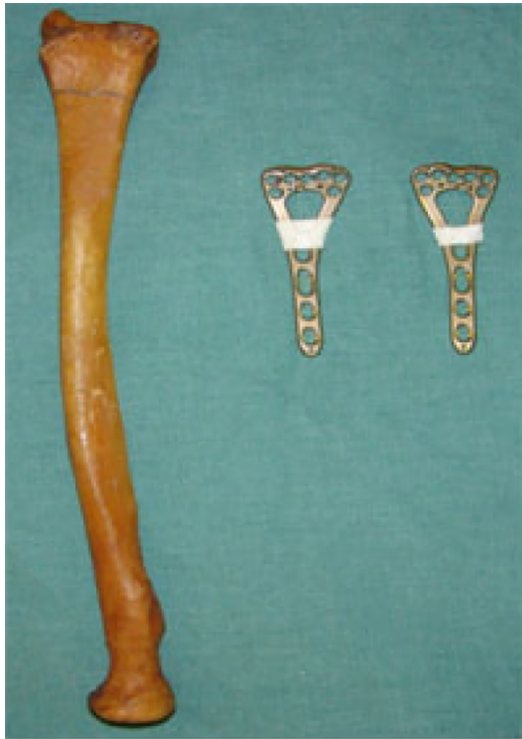

Figure 2. Left radius with a simulated simple distal metaphyseal fracture and two locked volar plates (one to the left side, and one to the right side; the laterality demarcation was covered).

value) in relation to the watershed line limit, measured in millimeters; the position of the plate in the coronal axis, with its centeredness measured also in millimeters at the immediately proximal orifice in relation to the oval orifice, with radial being identified by the letter R, and ulnar by the letter U; and the largest distance, measured in the sagittal plane between the plate and the bone (Figure 3).

Positioning and measurement example in the coronal plane proximal to the plate, taking as a parameter the green circle that indicates the locking orifice immediately proximal to the combined orifice on the plate. Blue lines indicate proximal (isthmus) and distal (distal articular surface width) parameters. A red line indicates the longitudinal axis of the radius, calculated by joining the center of the blue lines. A red dot inside a green circle indicates the center of the parameter used. In order to gauge proximal coronal positioning, one measures the length (in millimeters) of a straight line parallel to the proximal blue line between the black dot and the red line. If the black dot is to the left side of the red line, it is conventionally considered as radial (R); and if it is to the right side, ulnar (U) (Figure 3A). Positioning example for gauging the distance between the plate and the surface of the bone when seen in the profile, in the sagittal plane. The largest distance between the plate and the bone was

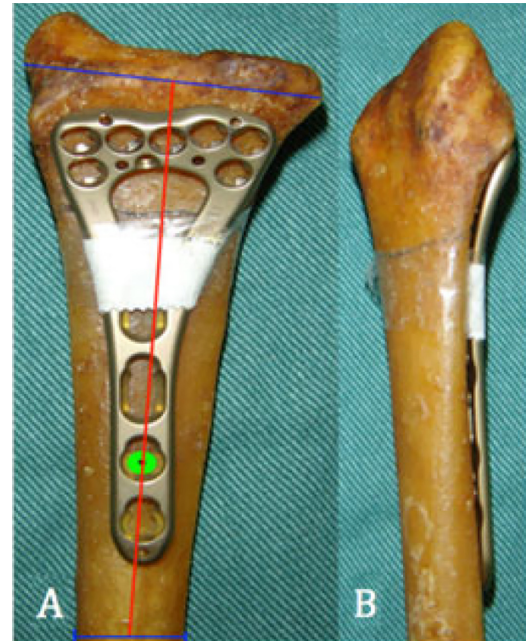

Figure 3. **A** – Positioning and measurement example in the coronal plane proximal to the plate. **B** – Positioning example for gauging the distance between the plate and the surface of the bone when seen in the profile, in the sagittal plane.

measured in millimeters (Figure 3B).

For analytic statistical analysis, we used SPSS V17, Minitab 16 and Excel Office 2010, and opted for conducting the Kruskal-Wallis, Spearman Correlation and Equality of Two Proportions tests. The level of significance was set at 0.05 (5%). Confidence intervals throughout the study were all constructed with 95% statistical confidence.

All procedures followed were in accordance with the ethical standards of the responsible committee on human experimentation (institutional and national) and with the Helsinki Declaration of 1975, as revised in 2008. Informed consent was obtained from all patients for being included in the study. The study was approved by the Ethics Research Committee of the hospital under protocol number 652.392.

Results

As to laterality, there were 17 correct positioning of the plate (Figure 4A), among which the average distance between the end of the plate and watershed line was +0.9 mm. The most frequently found positioning was precisely the one on the watershed line (mode = 0; n = 5), and the median was +0.5 mm. The average and median coronal positionings of the plate were 0.7 mm and 0.8 mm, respectively, radial to the midline of the radius. The average distance between the plate and the bone surface (profile; sagittal plane) was 1.0 mm. The most frequently found

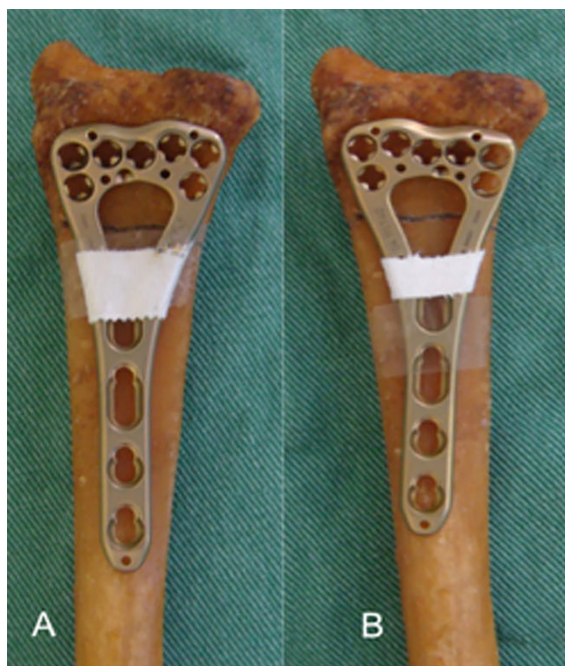

Figure 4. **A** – Example of correct positioning of the plate on the radius in relation to its laterality. **B** – Example of an erroneously positioned plate in relation to its laterality.

position was that of the plate well seated against the bone. (mode = 0; n = 5), and the median was 0.9 mm (Table 1).

13 residents erroneously positioned the plate in relation to its laterality (Figure 4B), one of whom (belonging to Group R1) positioned the volar plate on the dorsal surface of the radius.

Among the 17 correct positionings with respect to

the plate’s laterality, 5 were observed in Group R1; 7 in Group R2; and 5 in Group R3 (Table 2). However, a comparative analysis showed no statistical difference among the groups (Table 3).

Group R1’s average positioning, proximal to the watershed line, was -0.1 mm, whereas Group R2’s average was +2.1 mm, and Group R3’s average was +0.2 mm (Figure 5).

Regarding the coronal positioning of the plate, the average distances observed are as follows: 0.6 mm for Group R1; 0.9 mm for Group R2; and 0.6 mm for Group R3 – all of which are expressed radially in relation to the midline of the radius (Figure 6).

The average distances between plate and bone, seen in the sagittal plane, observed were: 1 mm for Group R1; 1.3 mm for Group R2; and 0.5 mm for Group R3 (Figure 7).

There was no statistically significant difference among the three groups regarding the following variables: distance from the watershed line, positioning in the coronal plane, plate-bone distance in the profile (Table 4).

Other differences without statistical significance are visualized in a Box-Plot graph (Figure 8).

There was a statistically significant correlation between Group R2 and the sum of the 17 residents that correctly positioned the plate in relation to its distance to the watershed line with the plate-bone distance in the profile. The correlations were 92.7% and 63.1%, respectively, indicating that the larger the distance from the end of the plate to the watershed line, the larger the distance between the plate and the bone as seen in the sagittal plane. These correlations are

Table 1

Distance between the plate and the watershed line, positioning in the coronal plane, and distance between the plate and the bone in the sagittal plane in situations where the positioning was correct regarding laterality

<i>n</i> = 17	<i>Distance between the plate and the watershed line (mm)</i>	<i>Coronal Positioning</i>	<i>Profile plate-bone distance (mm)</i>
Average	+0.9	0.7 R	1.0
Median	+0,5	0.9 R	0.9
Mode	0	0.5 R / 0.8 R / 1 R	0

R = radial.

Table 2

Correct and erroneous positioning distribution across Groups

<i>Side of the Plate</i>	<i>Erroneous positionings</i>		<i>Correct positionings</i>	
	<i>n</i>	<i>%</i>	<i>n</i>	<i>%</i>
R1	5	50	5	50
R2	3	30	7	70
R3	5	50	5	50

n = inclusion number.

Table 3

P values relative to the statistical differences between residency years.

	R1	R2
R2	0.361	
R3	1.000	0.361

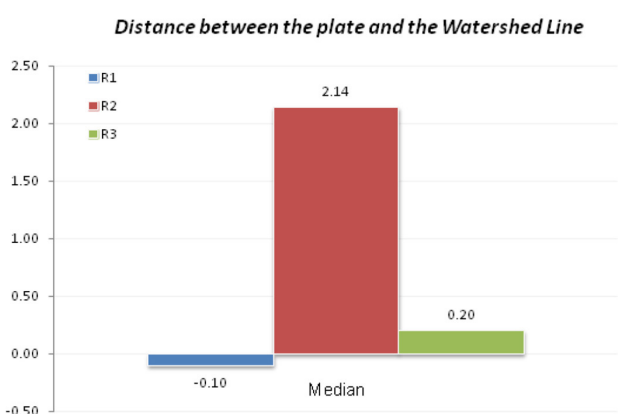


Figure 5. Comparison of the distances between the end of the plate and the watershed line across residency years.

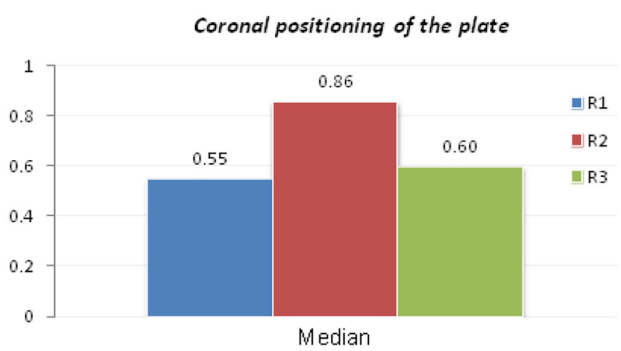


Figure 6. Comparison of plate positioning in the coronal plane across residency years.

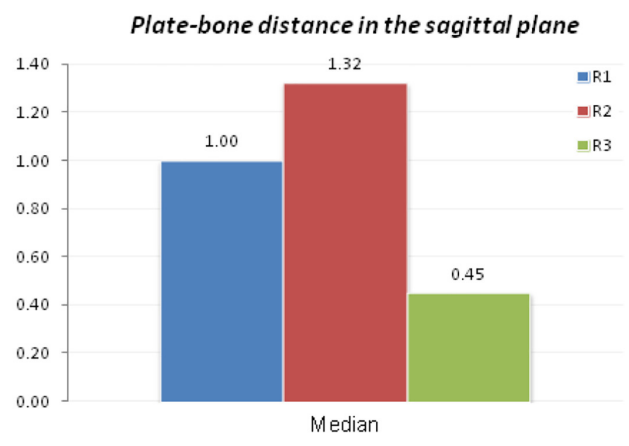


Figure 7. Comparison of results obtained by the residents for the distance between the plate and the bone as seen in the sagittal plane.

respectively classified as excellent and good (Table 5).

Discussion

Currently, the most frequently used approach for surgically treating distal radius fractures is the volar approach, which allows for better exploring fracture traces without causing the complications associated with the dorsal approach⁽¹⁹⁾.

Complications arising from the use of locked volar plate include postoperative loss of fixation or reduction, injury to the palmar cutaneous nerve (branch of the median nerve), carpal tunnel syndrome, attrition and rupture of flexor and extensor tendons, decreased range of motion, and loss of strength⁽²⁰⁾.

With the growth in popularity of volar plates over the last decade, new concepts and new anatomical terms have been adopted. Due to these anatomical accidents, new plates have been designed with an

Tabel 4

Comparison of the values obtained by Groups R1, R2 and R3 for the variables studied.

Residents		Average (mm)	Median (mm)	Standard Deviation	N	CI	P-value
Distance between the plate and the watershed line	R1	-0.1	-0.5	1.88	5	1.65	0.148
	R2	2.1	2.0	2.34	7	1.73	
	R3	0.2	0.0	1.10	5	0.96	
Coronal Positioning	R1	0.6 R	0.5 R	0.37 R	5	0.33 R	0.756
	R2	0.9 R	0.8 R	0.83 R	7	0.61 R	
	R3	0.6 R	0.5 R	0.65 R	5	0.57 R	
Profile plate-bone distance	R1	1.0	1.0	0.71	5	0.62	0.334
	R2	1.3	1.5	1.12	7	0.83	
	R3	0.5	0.3	0.62	5	0.55	

R = radial; CI = confidence interval.

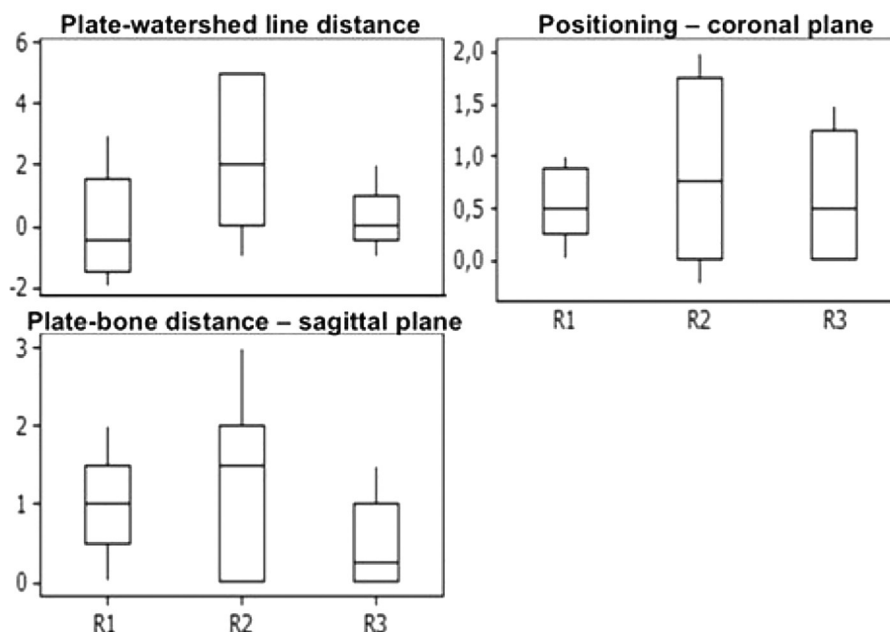


Figure 8. Box-Plot graph showing the values for the three variables studied across the three Groups of residents.

Table 5

Correlation between the plate–watershed line and plate–bone distances in the sagittal plane, across Groups and overall.

			Distance	Positioning
R1	Plate-watershed line distance	Corr (r):	15.4%	
		P-value	0.805	
R2	Plate-bone distance	Corr (r):	22.4%	68.8%
		P-value	0.718	0.199
R3	Plate-watershed line distance	Corr (r):	-7.3%	
		P-value	0.877	
Overall	Plate-bone distance	Corr (r):	92.7%	10.1%
		P-value	0.003	0.830
Overall	Plate-watershed line distance	Corr (r):	80.3%	
		P-value	0.102	
Overall	Plate-bone distance	Corr (r):	45.9%	50.0%
		P-value	0.437	0.391
Overall	Plate-watershed line distance	Corr (r):	16.6%	
		P-value	0.526	
Overall	Plate-bone distance	Corr (r):	63.1%	25.8%
		P-value	0.007	0.317

Corr (r): correlation.

opposite angulation to the articular surface of the distal third of the radius, while still respecting the watershed line. In our department, we mainly use first-generation single-row locked volar plates from Synthes®, whose angulation is parallel to the distal articular surface of the radius in the sagittal plane.

The residents, subject of the current study, have no previous experience with the next-generation material given to them, suitable for correct positioning, whose angulation is opposite to the surface of the distal third of the radius. In the current study, the residents were not shown any screws and, therefore, they could not

observe the orientation of the orifices, whose angles are more acute on the radial side of this plate.

No article evaluating the positioning of locked volar plates was found. Still, the literature on the correct anatomy of the watershed line and the correct positioning of these plates is scarce⁽¹⁷⁾.

It is important to note that, at the time of data collection, the first-year residents had only seven months of training in Orthopedics and Traumatology. Due to the rotating internship program adopted by the Department at the time the study was conducted, some of the residents had not yet completed their internship in Hand Surgery, which might have helped them to correctly position the plate or not.

For conducting the analytic statistical studies relative to the three variables, namely the distance between plate and watershed line, positioning in the coronal plane, and distance between the plate and the bone in the sagittal plane, we did not consider the 13 incorrect positionings.

Considering the 17 residents who correctly positioned the plate relative to its laterality, Group R1 was the only one whose average positioning was proximal to the watershed line, which excludes the risk of injury to tendons. Group R2's average positioning was too advanced, while Group R3's average was slightly distal to the watershed line. Only 5 positionings were correct and precisely on the watershed line. This was shown to be the resident's greatest difficulty.

Regarding the coronal plate positioning, Group R1 had the best average, slightly less than Group R3. Group R2 obtained the worst results. This fact was not attributed to any particular reason. We believe that the more parallel to the radio and the more centered the plate, the better its fitting to the contour of the volar surface of the radius. However, this was not the subject of our study.

Group R3 obtained the best average distance between the plate and the bone as seen in the sagittal plane, about half of Group R1's average value. Again, Group R2 had the worst results. We observed that the best results were obtained when the residents performed a sliding movement of the plate – this fact had the highest occurrence in Group R3. Nevertheless, this detail was not evaluated in the current study. 28.6% of the positioning in the sagittal plane were correct in Group R2, while in Group R1 those totaled only 20.0%.

In spite of its greatest distancing from the ideal average values and parameters observed, Group R2 had the largest number of residents with correct positioning in relation to the laterality of the plate. Notably, Group R1 obtained the best average distance between the watershed line and the end of the plate, as well as the best average coronal positioning. As for

Group R3, it achieved the best positioning results in the sagittal plane (distance between the plate and the bone in the profile) (Table 4; Figure 7).

Despite the differences among the three groups mentioned above, we found no statistical significance between them, most likely due to the small number of members in each group.

We found a statistically significant relation between the positioning in the coronal and sagittal planes, which indicates that the distance between the plate and the bone will be minimized and hence the distal end of the plate will be very close to the watershed line in the frontal plane, provided the plate incorrectly positioned on the volar surface of the radius. Obviously, there exist no two identical radiuses and when there is a deviation of the fracture, this parameter will then be altered. We can nonetheless affirm that the positioning of the plate in the two planes can even assist in reducing the fracture.

The large number of erroneous and incongruent positioning is worrisome considering that the residents, once they have completed their training in Orthopedics and Traumatology, will be able to conduct surgical procedures for treating distal radius fractures. However, they have neither the knowledge nor the experience for using plates whose design takes into consideration the watershed line anatomy, which are currently the most commonly used plates for treating those fractures at private healthcare institutions.

Conclusions

Slightly more than half of residents correctly identified the plate's laterality. The average distance between the plate and the watershed line was small, but associated with great variability. There was a tendency for the positioning of the proximal end of the plate to occur radially to the midline in the coronal plate. There is a correlation between the plate-bone distances, in the sagittal plane, and between the plate's distal end and the watershed line, in the coronal plane. Despite the differences observed among the groups of residents, there was no statistically significant difference between them.

References

1. Weinstein JN, Birkmeyer JD. *The Dartmouth Atlas of Musculoskeletal Health Care*. Chicago: American Hospital Publishing; 2000. 203p.
2. Cummings SR, Black DM, Rubin SM. Lifetime risks of hip, Colles', or vertebral fracture and coronary heart disease among white postmenopausal women. *Arch Intern Med*. 1989;149(11):2445-8.
3. Ray NF, Chan JK, Thamer M, Melton LJ 3rd. Medical expenditures for the treatment of osteoporotic fractures in the United States in 1995: report from the National Osteoporosis Foundation. *J*

- Bone Miner Res. 1997;12(1):24-35.
4. Lenoble E, Dumontier C, Goutallier D, Apoil A. Fracture of the distal radius. A prospective comparison between trans-styloid and Kapandji fixations. *J Bone Joint Surg*. 1995; 77(4):562-7.
 5. Beharrie AW, Beredjiklian PK, Bozentka DJ. Functional outcomes after open reduction and internal fixation for treatment of displaced distal radius fractures in patients over 60 years of age. *J Orthop Trauma*. 2004; 18(10):680-6.
 6. McCall TA, Conrad B, Badman B, Wright T. Volar versus dorsal fixed-angle fixation of dorsally unstable extra-articular distal radius fractures: a biomechanic study. *J Hand Surg Am*. 2007; 32(6):806-12.
 7. Kapandji A. Internal fixation by double intrafocal plate. L'ostéosynthèse par double embrochage intra-focal. Traitement fonctionnel des fractures non articulaires de l'extrémité inférieure du radius. *Ann Chir*. 1976; 30(11-12):903-8.
 8. Ring D, Jupiter JB, Brennwald J, Büchler U, Hastings H 2nd. Prospective multicenter trial of a plate for dorsal fixation of distal radius fractures. *J Hand Surg Am*. 1997; 22(5):777-84.
 9. Osada D, Viegas SF, Shah MA, Morris RP, Patterson RM. Comparison of different distal radius dorsal and volar fracture fixation plates: a biomechanical study. *J Hand Surg Am*. 2003;28(1):94-104.
 10. Jupiter JB, Marent-Huber M, LCP Study Group. Operative management of distal radial fractures with 2.4-millimeter locking plates. A multicenter prospective case series. *J Bone Joint Surg Am*. 2009; 91(1):55-65.
 11. Orbay JL. Volar plate fixation of distal radius fractures. *Hand Clin*. 2005; 21(3):347-54.
 12. Mudgal CS, Jupiter JB. Plate and screw design in fractures of the hand and wrist. *Clin Orthop Relat Res*. 2006; (445):68-80.
 13. Matityahu AM, Lapalme SN, Seth A, et al. How placement affects force and contact pressure between a volar plate of the distal radius and the flexor pollicis longus tendon: a biomechanical investigation. *J Hand Surg Eur*. 2013;38(2):144-50.
 14. Orbay JL, Touhami A. Current concepts in volar fixed-angle fixation of unstable distal radius fractures. *Clin Orthop Relat Res*. 2006; (445):58-67.
 15. Cross AW, Schmidt CC. Flexor tendon injuries following locked volar plating of distal radius fractures. *J Hand Surg*. 2008; 33(2):164-7.
 16. Soong M, Earp BE, Bishop G, Leung A, Blazar P. Volar locking plate implant prominence and flexor tendon rupture. *J Bone Joint Surg*. 2011; 93(4):328-35.
 17. Imatani J, Akita K, Yamaguchi K, Shimizu H, Kondou H, Ozaki T. An anatomical study of the watershed line on the volar, distal aspect of the radius: implications for plate placement and avoidance of tendon ruptures. *J Hand Surg Am*. 2012; 37(8):1550-4.
 18. Drobetz H, Kutscha-Lissberg E. Osteosynthesis of distal radius fractures with volar locking screw plate system. *Int Orthop*. 2003; 27(1):1-6.
 19. Musgrave DS, Idler RS. Volar fixation of dorsally displaced distal radius fractures using the 2.4 mm locking compression plate. *J Hand Surg*. 2005; 30(4):743-9.
 20. Sánchez T, Jakubietz M, Jakubietz R, Mayer J, Beutel FK, Grünert J. Complications after Pi Plate osteosynthesis. *Plast Reconstr Surg*. 2005; 116(1):153-8.

Article received: April 28, 2020

Article approved: July 02, 2021

Article published: July 03, 2021