

Fixation of mandibular fractures with lag screw: integrative review

Fixação de fraturas mandibulares com *lag screw*: revisão integrativa

Mariana Martins de Vitro¹ , Juli Emily Costa Guimarães¹ ,
Gustavo Grothe Machado¹ , Glauber Bareia Liberato da Rocha¹ 

ABSTRACT

Introduction: The mandible is the only movable bone of the face and plays a crucial role in masticatory, swallowing, phonation, and aesthetic functions. Mandibular fractures have the potential to cause numerous important changes. Angle, parasymphysis, body and condyle are the anatomical regions most affected by trauma. Rigid internal fixation (RIF) facilitated the process of treatment and recovery of mandibular functions. The lag screw fixation technique is based on the use of screws that manage to compress the bone fragments without the use of plates. **Objective:** This integrative review aims to review the fixation of mandibular fractures using the lag screw technique. **Method:** The search was performed in PubMed, Web of Science, Embase, and Cochrane databases considering the following terms combined with “and” or “or”: “mandibular fractures”; “lag screw”; “lag screw technique”; “treatment”; “fixation”. **Results:** Forty-nine articles were found in the database search and, after excluding duplicates, 31 remained. Thirteen articles were eligible for full-text reading, and nine were included in this review. The studies showed that the technique was associated with a lower number of intra and postoperative complications, provided safe RIF, greater compression between the stumps facilitating primary bone healing, and presented a shorter surgical time, and economic advantage. On the other hand, the technique proved to be sensitive and limited only to specific cases. **Conclusion:** The application of the lag screw fixation technique is an effective and stable RIF method that can be performed in the treatment of mandibular fractures.

Keywords: mandibular fracture, fracture osteosynthesis, jaw fracture bone, oral health.

RESUMO

Introdução: A mandíbula é o único osso móvel da face e possui papel crucial nas funções mastigatórias, de deglutição, fonação e estética. Fraturas mandibulares têm o potencial de causar inúmeras alterações importantes. Ângulo, parassínfise, corpo e côndilo são as regiões anatômicas mais acometidas por traumas. A fixação interna rígida (FIR) facilitou o processo de tratamento e a recuperação das funções mandibulares. A técnica de fixação *lag screw* é baseada no emprego de parafusos que conseguem comprimir os fragmentos ósseos sem a utilização de placas. **Objetivo:** Esta revisão integrativa teve como objetivo revisar a fixação de fraturas mandibulares por meio da técnica *lag screw*. **Método:** A busca foi realizada nas bases de dados PubMed, Web of Science, Embase e Cochrane considerando-se os seguintes termos combinados com “e” ou “ou”: “fraturas mandibulares”; “*lag screw*”; “técnica do parafuso *lag screw*”; “tratamento”; “fixação”. **Resultados:** Na busca nas bases de dados foram encontrados 49 artigos e, após a exclusão das duplicatas, restaram 31. Treze artigos foram elegíveis para leitura na íntegra e nove foram incluídos nesta revisão. Os estudos trouxeram como resultados que a técnica foi associada a um menor número de complicações intra e pós-operatórias, forneceu FIR segura, maior compressão entre os cotos facilitando a cicatrização óssea primária, apresentou menor tempo cirúrgico e vantagem econômica. Em contrapartida, a técnica mostrou-se sensível e limitada apenas para casos específicos. **Conclusão:** A técnica de fixação *lag screw* é um método de FIR eficaz e estável que pode ser realizado no tratamento de fraturas mandibulares.

Palavras-chave: fratura mandibular, osteossíntese de fraturas, fratura óssea da mandíbula, saúde bucal.

INTRODUCTION

The mandible is the only movable bone of the face and plays a crucial role in masticatory, swallowing, phonation and aesthetic functions. Due to its topography, anatomy and projection on the face, this bone is highly prone to fractures.

Mandibular trauma has the potential to cause numerous alterations, including disorders in the temporomandibular joint, dental malocclusion, difficulties in chewing, speaking, and swallowing, impaired facial aesthetics, pain, infections, among others⁽¹⁾.

¹Universidade de São Paulo, Faculdade de Medicina, Hospital das Clínicas - São Paulo (SP), Brazil.

Address for correspondence: Juli Emily Costa Guimarães. Rua Doutor Ovídio Pires de Campos, 225 - Cerqueira César, 05403-010 - São Paulo (SP), Brazil. E-mail: juliemily.ctbmf@gmail.com

Article received: 09/10/2023. Article approved: 11/13/2023. Article published: 12/18/2023.

Responsible Editor: Prof. Dr. Eitan Naaman Berezin (Editor-in-Chief).

The most common etiologies of mandibular trauma are car, motorcycle or cycling accidents, falls, interpersonal aggressions, and sports accidents. The etiology is usually strongly influenced by socioeconomic and cultural factors⁽²⁾.

Fractures can occur by a direct mechanism, when the fracture line occurs at the site of impact, or by an indirect mechanism, when the transmission of force causes fractures in the weakest points of the mandible, such as the condyle, a region of the mental foramen and edentulous areas⁽²⁾.

The anatomical regions of the mandible most affected by fractures are angle, parasymphysis, body, and condyle⁽³⁾. Factors such as the type of fracture line, the muscle action present in the traumatized region, the presence or absence of teeth, and the degree of displacement of bone fragments influence the choice of treatment⁽⁴⁾.

Historically, mandibular fractures were treated with a technique of reduction and closed fixation or maxillomandibular block (MMB). This method, in addition to generating a greater degree of discomfort for the patient, prolongs the time of mouth opening restriction. The emergence of rigid internal fixation (FIR) facilitated the recovery of mandibular function⁽⁵⁾. The use of miniplates for fracture fixation was first proposed by Michelet et al.⁽⁶⁾, and the technique was improved by Champy et al.⁽⁷⁾. The lag screw technique was described as an option for fixing mandibular fractures for the first time by Brons and Boering⁽⁸⁾. Niederdellmann et al. reintroduced the lag screw technique and suggested it to be an alternative to induction of osteosynthesis by using plates⁽⁹⁾. Ellis 3rd and Ghali later compared the fixation of mandibular fractures with lag screws and miniplates and found a smaller number of postoperative complications associated with the lag screw technique⁽¹⁰⁾.

The lag screw fixation technique is based on the use of screws that manage to compress bone fragments without the use of plates. For the applicability of the technique it is necessary to have two healthy cortical bones. The technique is considered an absolute rigid fixation and, therefore, sufficient bone availability is required for the placement of at least two lag screws. The screws are fixed parallel to each other and perpendicular to the fracture line, preventing overlaps and displacements when tightening the screws⁽¹¹⁾. Compression of bone fragments provides a more precise reduction, which seems to have advantages. This work carries out an integrative review about the fixation of mandibular fractures using the lag screw technique.

METHODS

This is an integrative review which describes the surgical procedures for the fixation of mandibular fractures with the lag screw technique.

Given this main subject, the review was conducted in the following steps:

1. Screening of bibliography in order to identify records related to the main subject and considering the inclusion and exclusion criteria;
2. Identification of the study types;
3. Analysis of the studies found in the screening;
4. Interpretation of results found in the literature;
5. Synthesis of the integrative review.

The search strategy was elaborated by two professionals, as well as the joint choice of databases. In case of disagreements between the authors, a third professional would give his/her opinion. The following descriptors selected in Medical Subject Headings (MeSH) were used for the search: mandibular fractures; treatment; fixation. The descriptors “lag screw” and “lag screw technique” were also considered in the search since the keywords commonly used in studies related to the topic. These descriptors were randomly combined with each other, forming search keys mediated by “and” or “or”, in order to provide a more advanced search. Different search strategies were applied in the following databases: PubMed, Web of Science, Embase and Cochrane.

The inclusion criteria for this review were:

- a) observational studies (retrospective/prospective/cohort), comparative studies and randomized clinical trials published between 2013 and 2023;
- b) articles that addressed surgical interventions using the lag screw technique for the treatment of mandibular fractures and that made a comparative analysis between the types of FIR and the lag screw technique;
- c) free availability of the manuscript on digital platforms. Articles that did not meet the inclusion criteria, duplicates, those that were not related to the topic (after analyzing the title, abstract or full text) and/or published before 2013 were excluded.

RESULTS

The database search was performed in May 2023 and resulted in 49 articles (Figure 1). Duplicate articles were excluded, and 31 records remained for title, abstract and keywords reading. After the selection process and accurate reading of the selected studies, nine articles met the eligibility criteria. Next, these studies were evaluated according to the inclusion criteria, 18 of which were excluded after reading the titles and abstracts. Thirteen records were selected for the final full-text analyses, and only nine met the previously determined review criteria. An informative table was produced containing the following

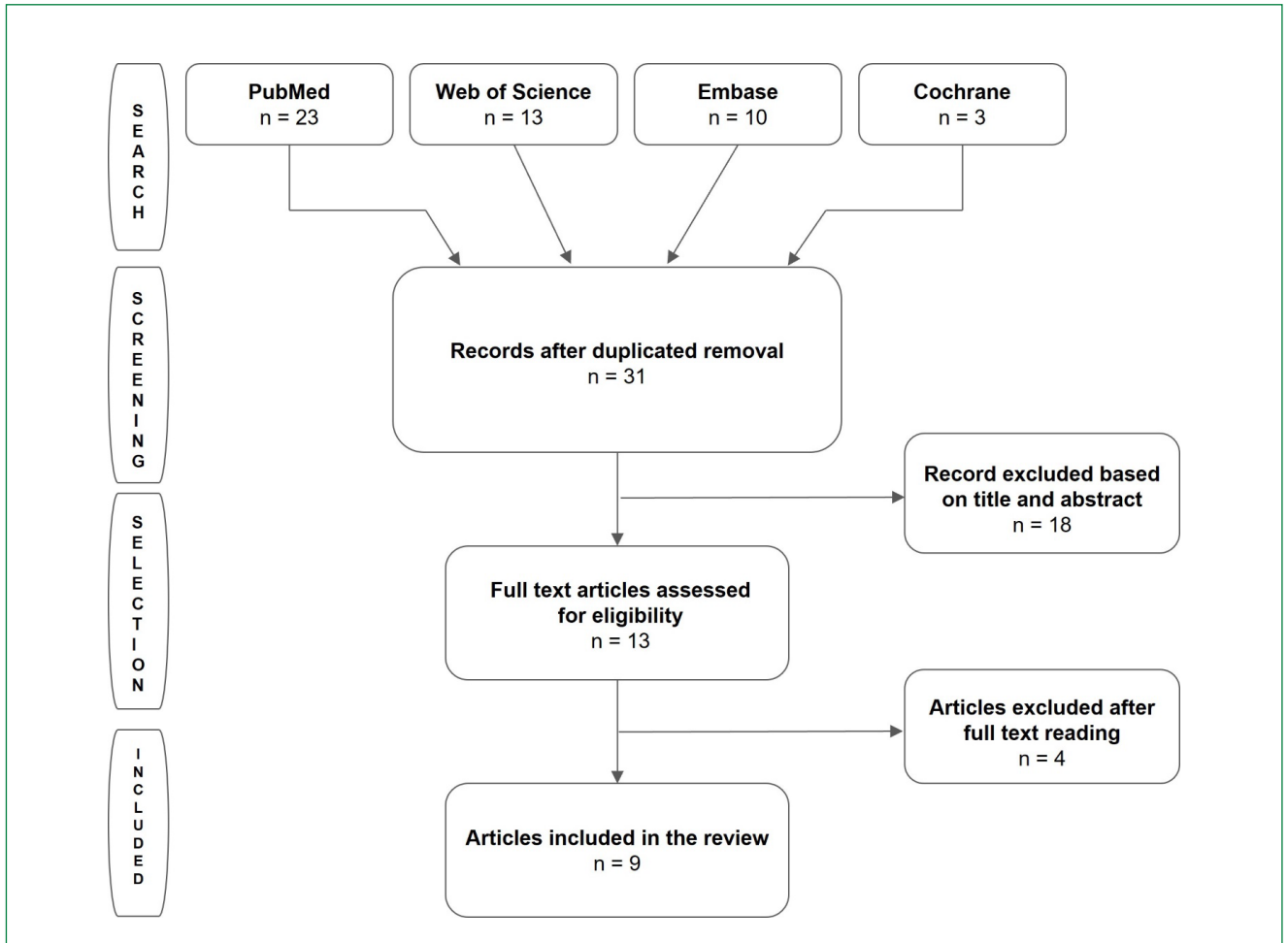


Figure 1 - Flow diagram of the review methodology.

main points: author and year, type of study, type and site of fracture, number of patients, fixation model and results (Table 1).

Fractures can be single, double or multiple and can be associated with fractures of other bones of the face or body. Other classifications of fractures distinguish them as simple or closed, compound or open, comminuted, greenstick, complicated or complex^(12,13). In addition, fractures can be: without displacement or without change in axis and complete bone contact along the fracture line; with deviation or change in axis and without bone contact and with interfragmentary failure; or with minimal or no contact between the fragments, presenting a defect or local bone loss⁽¹⁴⁾. The tension and compression pattern varies depending on where the force is applied to the jaw. In view of this, it is understood that the biophysics of the facial skeleton must be understood for the correct application of fixation devices so that fractures remain stable and no displacement of the stumps occurs during function⁽¹⁵⁾.

According to Ellis III (2020), FIR is defined as “any form of fixation applied directly to the bones that is strong enough

to prevent fragmentary movement along the fracture in active use of the skeletal structure⁹⁽¹¹⁾. FIR requires, as a mandatory component, open surgical exposure of the fractured site to reduce bone fragments, called open reduction, and subsequent fixation with specific devices. Once applied correctly, FIR can guarantee rigidity and stability of bone fragments throughout the entire healing period.

Initially, the lag screw technique was most used in the treatment of anterior mandibular fractures. The anatomy of this region facilitates and allows the fixation of the two devices, due to the ample space available. In rare cases where it is impossible to fix two screws, the Erich bar acts in the tension zone. There are three factors that make the lag screw technique possible in the anterior mandibular region: the bone curvature, which allows screws to be placed from one side to the other; the cortical thickness, which is wide and provides stability; and the low rate of anatomical risks⁽¹⁰⁾. Angle and body fractures can also be fixed with the lag screw technique. The fact that there is often less space available and/or proximity to the mandibular

Table 1 - Data from the studies included in the review.

Author	Study design	Type and location of fracture	n	Methods of fixation	Results
Danan et al. ⁽²⁰⁾	Retrospective cohort study	Simple; symphysis and parasymphysis	37	10 cases treated with lag screw; 27 cases treated with two miniplates	The overall bone union rate was 90% in treatment with the lag screw technique and 41% in cases treated with miniplates. In the group treated with miniplates, device exposure occurred in 15% of cases and fistula formation in 11%. No complications occurred in patients treated with the lag technique. Statistical analysis identified two variables associated with bone nonunion (observed on radiological examination): dentition and miniplate treatment technique.
Elsayed et al. ⁽¹⁶⁾	Retrospective study	Simple; isolated angle or associated with the symphysis, parasymphysis, body and subcondylar	30	Distribution in 3 groups: (A) a 2.0 mm miniplate with bicortical self-tapping screws 10-18 mm long; (B) a 2.3 mm plate; (C) a lag screw 2.4 mm in diameter and 28-40 mm in length	Group C had the shortest surgical time, followed by groups A and B. One patient in group A and another in group B developed post-surgical occlusal discrepancy. Two cases in group A developed wound dehiscence and one developed infection. One case from group B had device exposure. Three patients in group C and one in group B had sensory nerve involvement. The lag screw technique was associated with fewer complications, exhibited all the advantages of plate systems, and had a shorter operating time.
Mittal et al. ⁽¹⁵⁾	Prospective study randomized	Simple; symphysis and parasymphysis	20	Distribution in 2 groups: (A) two lag screws 2.5 mm in diameter and 24 mm in length; (B) two 2.5 mm plates	The surgical time for lag screw placement was shorter compared to plate placement. In the third postoperative month, the group treated with the lag technique showed better bite efficiency and better bone healing.
Carricondo et al. ⁽¹⁴⁾	Prospective observational study	Single or double; symphysis, parasymphysis, angle and body	318	155 patients treated with a lag screw and a miniplate; 163 patients treated with 2 miniplates	Modified lag screws were applied to double fractures and conventional miniplates to single fractures. The highest occurrence of complications was in the miniplate technique. The modified lag screw technique provided secure rigid fixation, greater compression between bone fragments, smaller post-surgical gap, faster ossification process and fewer post-operative complications.
El-Mahallawy and Al-Mahalawy ⁽¹⁸⁾	Randomized clinical trial	Simple or combined; symphysis, parasymphysis and subcondylar	21	Distribution in 3 groups: (HBS) Herbert screw 2.3 mm in diameter; (LS) two lag screws 2.7 mm in diameter; (MP) two 2.0 mm miniplates	The postoperative complications found were: altered sensitivity in the lower lip (28% in HBS and MP; 14% in LS), dehiscence (14% in HBS), root injury (28% in LS) and interfragmentary mobility (14% in LS). The greatest average gain in bone density was in the HBS group, followed by the LS and MP groups. Herbert screws have been shown to offer successful, minimally invasive treatment.
Tiwari et al. ⁽⁵⁾	Prospective randomized study	Simple; parasymphysis	50	Distribution in 2 groups: (A) two lag screws 2.5 mm in diameter and 22-26 mm in length; (B) two 2.0 mm diameter miniplates and 4 monocortical screws	The interfragmentary gaps in the postoperative period were greater in group B. The bite force was greater in group A. The average surgical duration was greater for group B. The cases treated with the lag screw technique showed recovery of efficiency faster bite. The lag screw technique proved to have good stability and rigidity, was less expensive and required less surgical time compared to miniplates.

Continue...

Table 1 - Continuation.

Author	Study design	Type and location of fracture	n	Methods of fixation	Results
Elsayed ⁽¹⁷⁾	Retrospective cohort study	Symphysis, parasymphysis, angle and body	33	Two lag screws, 2.4 mm in diameter and 28-40 mm in length (symphysis and parasymphysis); a lag screw 2.4 mm in diameter and 28-40 mm in length associated with the Erich bar in the tension region (angle and body)	The lag screw technique was most frequently applied to the anterior region of the symphysis and parasymphysis mandible (51.5%). Double screws were required for fixation of symphysis and parasymphysis fractures, while single screws were used for body and mandibular angle regions. Adequate occlusion was achieved in 96% of cases, except for one case treated with 1 lag screw. There was stability and alignment of the fixed segments. Four cases developed lower lip paresthesia, which resolved. Postoperative panoramic views revealed identifiable fracture lines within 3 months and satisfactory bone healing within six months.
Elsayed et al. ⁽¹⁹⁾	Cohort study	Symphysis and parasymphysis	64	(I) A 2.0 mm mini locking plate; (II) two 2.0 mm miniplates; (III) two lag screws, 2 mm in diameter and 24-38 mm in length; (IV) two 1.0 mm microplates	The technique that saved the most time was the lag screw followed by the microplate (with a mean/standard deviation — SD of 50.65 ± 4.152min). Statistically significant differences were observed in the parameters: wound dehiscence (4.7 and 3.1% of the two-miniplate and one-miniplate locking groups, respectively); mouth opening. Radiographic findings revealed considerable narrowing of the fracture line after the surgical approach in the groups treated with lag screw and a locking miniplate, while the fracture lines were easily identified in the groups treated with two 2.0 mm miniplates and two microplates.
Abd-Alwahab and Hassan ⁽²⁾	Prospective clinical study	Symphysis, parasymphysis and body	10	Two lag screws, 2 mm in diameter and 15, 17, 20, 21, 25, 29, 35 or 39 mm in length; a lag screw of 2 mm in diameter and 15-39 mm in length associated with the Erich bar in the tension region	The average age was 24.2 years and the ratio was 4:1 men to women. Parasymphysis and body oblique fractures were more common. Surgical time was shorter in intraoral approaches. Fracture stability intraoperatively was 60%, 80% after one month and 100% after six months. The occlusion was corrected in 90% of cases intraoperatively. Intraoperative complications resulting from drill fracture or incorrect drill position occurred in 20% of cases. No complications were observed in 90% of cases in the postoperative period.

canal in these regions for installing a second screw can make the application of this technique difficult. There are two options used to overcome this impasse: complementing the fixation with a bone plate fixed superiorly to the lag screw, in the tension zone; or the use of the Erich bar in the tension zone^(2,10).

The fixation of the screws to the bone is done with drills so that the hole created is at the most perpendicular angle possible with the fracture line. This guarantees efficient stability of the fragments, avoiding displacements when tightening the screws^(10,15). Ease and speed of fixation are advantages of the lag screw technique when compared to fixation with miniplates,

which require bone adaptation time for placement. Other advantages are the anatomically more precise reduction, greater stability and intimate contact of the stumps (providing primary bone healing), and lower cost⁽¹⁵⁾.

However, the presence of comminution and bone loss are contraindications to the technique⁽¹⁵⁾. This is because the lag screw fixation technique is based on the compression of bone fragments and, if there is bone failure due to comminution or lack, compression will not be achieved, and there may be fragmentary displacement and shrinkage of the fracture interval, resulting in occlusal dysfunctions⁽¹⁰⁾.

DISCUSSION

Adequate treatment of mandibular fractures should consider perfect anatomical reduction, stable functional fixation, mobilization of fractured segments, minimization of complications and immediate function achievement. For this, knowledge of surgical anatomy, biomechanical forces, occlusion, and the presence of a third molar in the fracture line is essential. Limited access to the region must also be considered. Therefore, the ideal method for the treatment of mandibular fractures is still controversial, and the existence of masticatory forces with the potential for displacement of the fractured bone stumps is a factor to be considered⁽¹⁶⁾.

Currently, most of the fixation systems available offer advantages, such as ease of adaptation, minimal alteration between the bone and occlusal relationship, low chance of maladaptation and high stability without decreasing blood supply, and excessive bone pressure. In this sense, fixation with the lag screw technique provides compression in the axial direction and load sharing at the fracture site, at the expense of directing the fixation forces along the long axis of the screw, providing greater stability⁽¹⁶⁾.

Conventional lag screws have a proximal axis, close to the head, without threads and the distal axis with threads⁽¹¹⁾. However, the study by Elsayed used modified lag screws, with threads along their length, which is justified by greater accessibility and availability⁽¹⁷⁾. The traditional lag screw technique, with the use of two screws installed parallel to each other and perpendicular to the fracture line, as recommended by Niederdellmann et al.⁽⁹⁾, was used in most of the studies included in this review. Abd-Alwahab et al. found the need to associate, in 30% of cases, a lag screw with the Erich bar, which acts as a tension band, as the installation of a second lag screw was made difficult due to its proximity to the mandibular nerve and the impossibility of fixing the screw⁽²⁾. Elsayed et al. treated mandibular angle fractures with only one lag screw fixed on the upper edge of the mandible or tension zone, and found greater stability interfragmentary compared to the groups treated with miniplates⁽¹⁶⁾. Carricondo et al. treated mandibular fractures using the modified lag screw in the mandible base region (compression zone) and a miniplate in the alveolar base region (tension zone) and observed a faster healing in the region⁽¹⁴⁾.

To El-Mahalawy et al., the advantages of the lag screw technique include unsurpassed interfragmentary compression, functional stability, rapid application, low cost, low complication rate, anatomically more accurate reduction, elimination of a possible lingual gap and low rate of displacement⁽¹⁸⁾. Elsayed et al. found as advantages the provision of strong and rigid fixation, with great stabilization, primary bone consolidation,

the need for minimal use of devices and lower cost and surgical time⁽¹⁹⁾. In turn, Carricondo et al. highlighted as positive points of the technique the ease of access to the material and the high rate of stability, depending on the number of screws applied, the placement method, the type of mono or bicortical fixation and the compression force applied on the lag screws during placement⁽¹⁴⁾.

As disadvantages, there is a chance of fracture of the proximal segment when tightening the screw or drill⁽¹⁴⁾. However, when citing this negative point, the authors proposed alternatives to avoid such events: the need to maintain a minimum distance of 5 mm between the fracture line and the area where the lag screw will be inserted, and the best orientation of the drill, respectively⁽¹⁴⁾. Furthermore, Elsayed et al. emphasized the sensitivity of the technique, restricting its use and making it impossible to fix fractures that are comminuted or very fragmented, old or late, or with missing segments⁽¹⁹⁾.

As limitations, a single study proposes the difficulty of removing the lag screws after healing, justifying that this factor should not actually be considered a problem, since in the study none of the 33 patients treated with the technique needed to have the screws replaced⁽¹⁷⁾.

Regarding the bone healing, Carricondo et al.⁽¹⁴⁾ described that a space smaller than 1 mm between the bone fragments is tolerable for good ossification and healing through primary bone healing to occur, considering the muscle forces that act on the mandible. In contrast, when the existing space is greater than 1 mm, the primary and secondary bone healing processes are combined⁽¹⁴⁾. According to Tiwari et al., the lag screw technique allows a greater approximation of the fractured stumps⁽⁵⁾ as the compression force applied by the screw provides intimate contact between the stumps, as corroborated by Abd-Alwahab et al.⁽²⁾. Similarly, Elsayed, when evaluating a different form of fixation of anterior mandibular fractures, found⁽¹⁷⁾ a small interfragmentary gap at one month postoperatively in patients treated with miniplates, and in those patients treated with lag screws and microplates there was no formation of the bone callus^(17,19).

When observing the surgical time for the installation of internal fixation, Mittal et al. found that in case of fractures of the symphysis, parasymphysis and angle, fixation with the lag screw technique was faster compared to fixation with miniplates. The authors justified this time discrepancy by the need for bends for the exact adaptation of the miniplates to the bone surface⁽¹⁵⁾. Abd-Alwahab et al., in turn, evaluated the difference in surgical time in relation to the type of access. The extraoral access required more time, due to the need for dissection to expose the fracture line⁽²⁾. Likewise, Elsayed et al. argued that the intraoral incision, in addition to providing

better aesthetics, occult healing and maintaining good surgical exposure, is faster to perform as it eliminates the time required for dissection⁽¹⁹⁾.

As trans-operative complications, Abd-Alwahab et al. brought the risk resulting from fracture or incorrect position of the drill during fixation. These events occurred in 20% of the cases in their study, and in 90% of them there was an occlusal change, which was corrected intraoperatively. A single case was registered with alteration of the occlusion in the postoperative period, due to the incorrect positioning of the screw, which was solved with intermaxillary block and Erich bar⁽²⁾. Elsayed et al. reported a single case of lag screw fracture⁽¹⁹⁾.

Postoperative complications have been described. In the work by Carricondo et al., in the group treated with miniplates the complications were: 6.7% intolerance to the material, 1.9% hypoesthesia of the mental nerve, 0.6% suture dehiscence, 3.7% pseudarthrosis, 3.7% malocclusion, 1.2% bone defect, 4.9% infection and 1.2% osteomyelitis. In the group treated with the lag screw associated with the miniplate, only one patient had intolerance to the osteosynthesis materials. In other words, patients treated with miniplates had an 8.8 to 19.5 times greater risk of developing complications compared to patients treated with the modified lag screw technique⁽¹⁴⁾. This information is in line with the findings of Tiwari et al., who found a lower number of postoperative complications associated with the lag screw technique⁽⁵⁾.

Regarding the exposure rates of the fixation device and fistula formation, these were lower for the lag screw technique than for fixation using miniplates in the study by Danan et al. Furthermore, the authors found that all cases that evolved with fistula formation (11%) and exposure of the fixation device (15%) occurred in patients treated with fixation using miniplates⁽²⁰⁾. Similarly, in the work by Elsayed, wound dehiscence occurred in five and three cases in the groups treated with one locking miniplate and two 2.0 mm miniplates, respectively⁽¹⁷⁾. In patients treated with lag screws and microscrews, dehiscence did not occur. This fact can be explained by the smaller size of the lag screw and the micro screw compared to the miniplates, requiring less tissue manipulation and providing easy adaptation, less tension in the wound area, and less interruption of the blood supply⁽¹⁹⁾. In the study by El-Mahalawy and Al-Mahalawy, there were no cases of wound dehiscence as a postoperative complication when treating 21 patients with anterior mandible fracture with lag or Herbert screws⁽¹⁸⁾.

Malocclusion was one of the variables observed in the studies by Danan et al.⁽²⁰⁾, Elsayed et al.⁽¹⁶⁾, Carricondo et al.⁽¹⁴⁾, El-Mahalawy and Al-Mahalawy⁽¹⁸⁾, Elsayed⁽¹⁷⁾ and Elsayed et al.⁽¹⁹⁾. In none of the studies was malocclusion observed in cases treated with the lag screw technique.

Sensory nerve injury was the most common complication, found in about 30% of mandibular angle fracture cases treated with lag screw in the study by Elsayed⁽¹⁶⁾. The authors related this occurrence with the limited intraoral access, requiring greater manipulation and tissue traction and offering a greater chance of damage to the nervous structures during insertion of the lag screw⁽¹⁶⁾. In another work by Elsayed et al., nerve damage to the mental nerve occurred in 28% of cases treated with one locking miniplate, in 16% of cases treated with two miniplates, in 6% of cases treated with two lag screws, and in 10% of cases treated with two microplates⁽¹⁹⁾. In this study, the authors attributed the chance of injury to nerve structures to the possible displacement of fractures and the longer operative time, causing stretching of the nerves close to or associated with the fracture and adjacent soft tissues during the surgical approach⁽¹⁹⁾.

When considering post-fixation stability and the occurrence of loosening and loosening of fixation devices, Mittal et al. observed a case of mobility in the group treated with two miniplates that was caused by infection, leading to screw loosening. In general, in most cases reported in the literature, loosening of lag screws is related to the existence of infected teeth in the fracture line, unlike the justification for loosening miniplates, often associated with excessive bone compression causing osteolysis⁽¹⁵⁾. Confirming this statement, Elsayed et al. found a greater chance of screw loosening in the fixation technique with miniplates, which was explained by the excessive pressure of the plate against the bone⁽¹⁶⁾.

Many of the studies included in this review had as their exclusion criteria any adverse factor that could alter the normal bone healing process, with the exception of a single study. Danan et al. included cancer patients undergoing chemotherapy treatment in their study and found an overall bone union rate of 90% for fixation with the lag screw technique and 41% for cases fixed with two miniplates. For the authors, even though chemotherapy can impair healing, the intimate bone contact provided by the fixation with the lag screw technique seems to be a more appropriate option for treatment to achieve primary bone consolidation⁽²⁰⁾.

CONCLUSION

The lag screw technique for the fixation of mandibular fractures can achieve high functional stability, appropriate bone compression, excellent treatment results, and limited complications.

Among the advantages of this technique, we can mention: rapid application and shorter surgical installation time; low cost; financial savings; minimal use of devices; easy access to

material; low rate of complications; minimal risk of displacement of the stumps after fixation; and accurate anatomical reduction, providing primary bone healing due to the compression mechanism. On the other hand, there is a small risk of fracture of the proximal segment when tightening the screw, or of fracture of the drill at the time of fixation, difficulties that

can be overcome by respecting a minimum distance and performing a better orientation of the drill, respectively. In this sense, a possible limitation of the technique is the difficulty in angling the drill for drilling and subsequent fixation of the screw. Finally, the sensitivity of the technique and its restricted applicability to specific cases are also limitations.

Funding: MMV and JECG are the recipients of grants from the Ministério da Saúde (Brazil).

Conflict of interest: The authors have no conflict of interests to disclose.

Authors' contributions: MMV: Conceptualization, Formal analysis, Investigation, Methodology, Project administration, Writing – original draft, Writing – review & editing. JECG: Conceptualization, Formal analysis, Methodology, Investigation, Supervision, Writing – original draft, Writing – review & editing. GGM: Supervision, Writing – review & editing. GBLR: Methodology, Supervision, Writing – review & editing.

REFERENCES

- Mendonça JCG, Jardim ECG, Manrique GR, Lopes HB, Freitas GP. Acesso cirúrgico para tratamento de fraturas mandibulares: revisão de literatura. *Arch Health Invest.* 2013;2(2):19-23. <https://doi.org/10.21270/archi.v2i2.134>
- Abd-Alwahab HT, Hassan TAL. The outcomes of the lag-screw use for treatment of the mandibular symphysis, parasymphysis and oblique body fractures. *J Res Med Dent Sci.* 2021;9(6):44-53.
- Sakr K, Farag IA, Zeitoun IM. Review of 509 mandibular fractures treated at the University Hospital, Alexandria, Egypt. *Br J Oral Maxillofac Surg.* 2006;44(2):107-11. <https://doi.org/10.1016/j.bjoms.2005.03.014>
- Lamounier LC. Métodos de fixação de fraturas de ângulo mandibular: revisão de literatura. Monografia (Curso de Especialização). Belo Horizonte: Universidade Federal de Minas Gerais, Faculdade de Odontologia; 2014.
- Tiwari M, Meshram V, Lambade P, Fernandes G. Titanium lag screw versus miniplate fixation in the treatment of anterior mandibular fractures. *J Oral Maxillofac Surg.* 2019;77(5):1031-9. <https://doi.org/10.1016/j.joms.2019.01.001>
- Michelet FX, Deymes J, Dessus B. Osteosynthesis with miniaturized screwed plates in maxillo-facial surgery. *J Maxillofac Surg.* 1973;1(2):79-84. [https://doi.org/10.1016/s0301-0503\(73\)80017-7](https://doi.org/10.1016/s0301-0503(73)80017-7)
- Champy M, Loddé JP, Schmitt R, Jaeger JH, Muster D. Mandibular osteosynthesis by miniature screwed plates via a buccal approach. *J Maxillofac Surg.* 1978;6(1):14-21. [https://doi.org/10.1016/s0301-0503\(78\)80062-9](https://doi.org/10.1016/s0301-0503(78)80062-9)
- Brons R, Boering G. Fractures of the mandibular body treated by stable internal fixation: a preliminary report. *J Oral Surg.* 1970;28(6):407-15. PMID: 5266458.
- Niederdelmann H, Schilli W, Düker J, Akuamo-Boateng E. Osteosynthesis of mandibular fractures using lag screws. *Int J Oral Surg.* 1976;5(3):117-21. [https://doi.org/10.1016/s0300-9785\(76\)80059-2](https://doi.org/10.1016/s0300-9785(76)80059-2)
- Ellis 3rd E, Ghali GE. Lag screw fixation of anterior mandibular fractures. *J Oral Maxillofac Surg.* 1991;49(1):13-21; discussion 21-2. [https://doi.org/10.1016/0278-2391\(91\)90259-o](https://doi.org/10.1016/0278-2391(91)90259-o)
- Ellis III E. Fixação rígida versus não rígida. In: Miloro M, Ghali GE, Larsen PE, Waite PD. *Princípios de cirurgia bucomaxilofacial de Peterson.* São Paulo: Santos; 2020. p. 303-14.
- Smith BM, Deshmukh AM, Barber HD, Fonseca RJ. Fraturas mandibulares. In: Fonseca RJ, Walker R V, Dexter Barber H, Mesa L, Adjunct A. *Trauma bucomaxilofacial.* 4ª. ed. Rio de Janeiro: Guanabara Koogan; 2015. p. 293-330.
- Bell RB. Tratamento contemporâneo das fraturas mandibulares. In: Miloro M, Ghali GE, Larsen PE, Waite PD. *Princípios de cirurgia bucomaxilofacial de Peterson.* São Paulo: Santos; 2020. p. 331-58.
- Carricondo ARG, Bravo FJQ, Gálvez FE, Carreño TP, Rodriguez RA. A comparative study between traditional fixation with miniplates and modified lag screws for the treatment of mandibular fractures. *Clin Oral Investig.* 2018;22(3):1503-11. <https://doi.org/10.1007/s00784-017-2243-7>
- Mittal G, Aggrawal A, Garg R, Sharma S, Rathi A, Sharma V. A clinical prospective randomized comparative study on osteosynthesis of mandibular anterior fractures following open reduction using lag screws and miniplates. *Natl J Maxillofac Surg.* 2017;8(2):110-6. https://doi.org/10.4103/njms.NJMS_38_17
- Elsayed SA, Mohamed FI, Khalifa GA. Clinical outcomes of three different types of hardware for the treatment of mandibular angle fractures: a comparative retrospective study. *Int J Oral Maxillofac Surg.* 2015;44(10):1260-7. <https://doi.org/10.1016/j.ijom.2015.07.005>

17. Elsayed SAH. Cortical lag screw fixation for the management of mandibular injuries. *J Korean Assoc Oral Maxillofac Surg.* 2020;46(6):393-402. <https://doi.org/10.5125/jkaoms.2020.46.6.393>
18. El-Mahallawy Y, Al-Mahalawy H. Herbert cannulated bone screw osteosynthesis in anterior mandibular fracture treatment: a comparative study with lag screw and miniplate. *J Oral and Maxillofac Surg.* 2018;76(6):1281.e1-1281.e8. <https://doi.org/10.1016/j.joms.2018.01.034>
19. Elsayed SAH, Elsayed EH, Altaweel AA. Stabilization of anterior mandibular fracture using different osteosynthesis devices: perioperative clinical notes. *Oral Maxillofac Surg.* 2021;25(3):303-11. <https://doi.org/10.1007/s10006-020-00917-9>
20. Danan D, Mukherjee S, Jameson MJ, Shonka Jr DC. Open reduction internal fixation for midline mandibulotomy: lag screws vs plates. *JAMA Otolaryngol Head Neck Surg.* 2014;140(12):1184-90. <https://doi.org/10.1001/jamaoto.2014.2005>

